

AIPPG.com™ AIIMS NOV 2004 released answers, Discuss these at AIPPG.net forums!

AIPPG.com AIIMS NOV 2004 ANSWERS, ANSWERS TO AIIMS NOVEMBER 7th EXAMINATION. RELEASED BY AIPPG. ALL ANSWERS ARE COPYRIGHT AIPPG.com©

Explanations and answers (December 17, 2004 11: 00 PM IST)
About 2-4 answers are either not marked or mentioned doubtful, we will try and solve these as soon as possible. DO mail in your contributions at aippg@aippg.info.

As usual all answers and explanations come first here and then in any book!

AIPPG™ is a registered trademark of AIPPG.com.
Discuss these answers at [AIIMS NOV forum](http://www.aippg.net/forum/viewforum.php?f=9)
<http://www.aippg.net/forum/viewforum.php?f=9>

Some answers are not marked now, and this paper will be updated very soon again.

1. When a person has suspended himself by applying ligature around neck so that the point of suspension (Knot) is situated in the region of the occiput. Such a hanging is called as:
 - a. Typical
 - b. Atypical
 - c. Partial
 - d. Incomplete

Ans 1

2. Which of the following statements about blood grouping is not correct?
 - a. It can be used to resolve confusion of identity in alleged exchange of babies in maternity unit.
 - b. It is the method to **conclusively** fix the paternity.
 - c. It can assist in matching fragmented human remains in mass disaster.
 - d. It can help to show whether blood stain on the weapon belongs to the suspect or victim.

Ans 2, (Also keep in mind: whenever blanket (always, only etc etc) terms are used in an MCQ it is usually false)

3. The dead body of a murdered person is brought for preservation in mortuary. Which of the following statements is not correct?
 - a. The body should be stored averagely at 4°C .
 - b. The body can be embalmed before postmortem.
 - c. The body should be never undressed before the forensic doctor has seen it.
 - d. The body can be stored at 20° C to preserve it for long duration.

Ans 2

4. An eleven year old rape victim is brought to casualty for medical examination. The medical officer is required to do the following things. Except:
 - a. The consent is to be taken from the patient.
 - b. The patient should be examined in presence of a female attendant.
 - c. The patient should be given necessary emergency treatment.
 - d. All the necessary forensic samples should be collected.

Ans 1

5. A body is brought for autopsy with history of poisoning. On postmortem examination, there is dark brown postmortem staining and garlic odour in stomach. In this case the poisoning is most likely due to:
 - a. Hydrocyanic acid
 - b. Carbon dioxide.
 - c. Aniline dye.
 - d. Phosphorus.

Ans 4

6. A 13-year-old boy has bilateral gynecomastia. His height is 148 cm, weight 58 kg: the sexual maturity rating is stage 2. The gynecomastia is most likely due to:
 - a. Prolactinoma
 - b. Testicular tumor
 - c. Pubertal gynecomastia
 - d. Chronic liver disease.

Ans 3, SMR 2 is normal in pubertal Gynecomastia.

7. A 9-year-old boy present with growth retardation and propensity to hypoglycemia. Physical examination reveals short stature, micropenis, increased fat and high-pitched voice. The skeletal survey reveals bone age of 5 years. Which of the following is most appropriate diagnosis?
 - a. Malabsorption.
 - b. Growth hormone deficiency
 - c. Adrenal tumor
 - d. Thyroxin deficiency

Ans 2

8. A 50 year old male with type 2 diabetes mellitus is found to have 24-hours urinary albumin of 250 mg. which of the following drugs may be used to retard progression of renal disease.
 - a. Hydrochlorothiazide
 - b. Enalapril
 - c. Amiloride
 - d. Aspirin.

Ans 2

9. Which of the following is the most common extrarenal involvement in autosomal dominant polycystic kidney disease?
 - a. Mitral valve prolapse.
 - b. Hepatic cysts
 - c. Splenic cysts
 - d. Colonic diverticulosis.

Ans 2 (UPDATE) Harrison 16th Page1696,

"Hepatic cysts occur in 50-70 % of patients" [Colonic diverticuli are simply mentioned as common] [In earlier edition colonic diverticulosis was mentioned as most common, but now the word most has been deleted.]

10. All of the following can cause hypercalcemia, except:
 - a. Prolonged immobilization.
 - b. Tumor lysis syndrome.
 - c. Sarcoidosis
 - d. Multiple myeloma.

Ans 2

11. Which one of the following is correct regarding Eaton-Lambert syndrome?
 - a. It commonly affects the ocular muscles.
 - b. Neostigmine is the drug of choice for this syndrome.

- c. Repeated electrical stimulation enhances muscle power in it.
- d. It is commonly associated with adenocarcinoma of lung.

Ans 3

12. Which of the following statements is correct regarding chronic granulomatous disease?
- a. It is an autosomal dominant disease.
 - b. It is characterized by abnormal bacterial phagocytosis.
 - c. Recurrent streptococcal infections are usual in this disease.
 - d. Nitroblue tetrazolium test is useful for screening.

Ans 4

13. All of the following are true about therapy for tuberculosis except:
- a. "Flu like syndrome" is usually seen in people taking rifampicin on daily basis,
 - b. Ethambutol accumulates in renal failure.
 - c. Hyperuricemia is a recognized side effect of pyrazinamide.
 - d. Red-green color impairment is an early sign of ethambutol induced optic neuritis.

Ans 1

Ref Katzung, Flu like syndrome is seen in people taking rifampin on alternate basis (as in our DOTS). In Harrison it is given that if FLU like syndrome occurs while taking therapy > Switch to twice weekly dose. Other options are very characteristic (also mentioned in ((Also Cotran says that the flu like symptoms may require switching to a daily regimen))

14. A 60 years old man with rheumatic mitral stenosis with atrial fibrillation is on therapy for a fast ventricular rate. While on treatment, he developed a regular pulse of 64 beats per min. the most likely drug being administered was
- a. Verapamil.
 - b. Digoxin.
 - c. Carvedilol.
 - d. Propranolol.

Ans 2

15. In a patient with Listeria meningitis who is allergic to penicillin, the antimicrobial of choice is:
- a. Vancomycin
 - b. Gentamicin
 - c. Trimethoprim-sulphamethoxazole.
 - d. Ceftriaxone.

Ans 3, ref Harrison.

Ceftriaxone is NOT used as monotherapy for Listeria for it is not effective.

16. Ropinirole is the most useful for the treatment of:
- a. Parkinson's disease
 - b. Wilson's disease
 - c. Hoffman's syndrome
 - d. Carpal tunnel syndrome.

Ans 1

17. All of the following can cause of megakaryocytic thrombocytopenia except:
- a. Idiopathic thrombocytopenic purpura.
 - b. Systemic lupus erythematosus.

- c. Aplastic anemia
- d. Disseminated intravascular coagulation. (DIC)

Ans 3, It is very well mentioned that

- 1) In aplastic anemia cells are abnormal, nucleated cells with pancytopenia > suspect Myelodysplastic syndromes (Harrison / CMDT)
- 2) Also we found that any condition which increases peripheral consumption of platelets will cause increased release of nucleated immature platelets in circulation.

18. The following test may be abnormal in disseminated intravascular coagulation **except**:

- a. Prothrombin time.
- b. Activated partial thromboplastin time.
- c. D-dimer levels.
- d. Clot solubility.

Ans 4

19. Which one of the following gram positive organisms is the most cause of urinary tract infection (UTI) among sexually active women?
- a. Staphylococcus epidermidis
 - b. Staphylococcus aureus
 - c. Staphylococcus saprophyticus.
 - d. Enterococcus.

Ans 3. Ref Harrison saprophyticus causes 10-15 % of UTI in young females.

20. Laboratory evaluation for the differential diagnosis of chronic myeloproliferative disorders includes all of the following except:
- a. Chromosomal evaluation
 - b. Bone marrow aspiration
 - c. Flow cytometric analysis
 - d. Determination of red blood cell mass.

Ans 3 (Flow cytometric analysis is used to detect absence / presence of CD markers such as CD 55 absence in PNH)

21. A patient of acute leukemia is admitted with febrile neutropenia. On day four of being treated with broad-spectrum antibiotics, his fever increases. X-ray chest shows bilateral fluffy infiltrates. Which of the following should be the most appropriate next step in the management.
- a. Add antiviral therapy
 - b. Add antifungal therapy
 - c. Add cotrimoxazole
 - d. Continue chemotherapy.

Ans 3 [The fight here is between two options 3 and 4. Antifungal (option 2) is added after fever of febrile neutropenia continues beyond 7 days. PCP can occur in Febrile neutropenia.

"X-ray chest shows bilateral fluffy infiltrates" this means ..

CMDT mentions in P Jiveroci (carinii) essentials of diagnosis *Bilateral Perihilar infiltrates*

Still adding cotrimoxazole is a better option in our opinion, Comments welcome by feedback form. Or email aippg [@] aippg.com.

22. A patient is admitted with 3rd episode of deep venous thrombosis. There is no history of any associated medical illness. All of the following investigations are required for establishing the diagnosis, except:

- Protein C deficiency
- Antithrombin III deficiency
- Antibodies to factor VIII
- Antibodies to cardiolipin.

Ans 3, Antibodies to factor VIII will cause bleeding not thrombosis. It is the prime cause of acquired hemophilia.

23. Humoral immunodeficiency is suspected in a patient and he is under investigation. Which of the following infections would not be consistent with the diagnosis?

- Giardiasis
- Pneumocystis carinii pneumonia
- Recurrent sinusitis.
- Recurrent subcutaneous abscesses.

Ans 2

24. A patient presents with melaena, normal renal function, hypertension and mononeuritis multiplex. The most probable diagnosis is:

- Classical polyarteritis nodosa
- Microscopic polyangitis.
- Henoch-Schonlein purpura.
- Buerger's disease.

Ans 1, Normal renal function, hypertension suggest PAN not microscopic polyangitis. (also related question Dactylitis occurs in PAN)

25. A 27-year-old man is noted to have blood pressure of 170/100 mmHg. He has prominent aortic ejection click and murmurs heard over the ribs on both sides anteriorly and over the back posteriorly. In addition, the pulses in the lower extremities are feeble and he complains of mild claudication with exertion. The most likely diagnosis is:

- Atrial septal defect.
- Aortic stenosis
- Coarctation of the aorta
- Cardiomyopathy.

Ans 3

26. All of the following statements are true regarding Staphylococci except:

- A majority of infections caused by coagulase-negative Staphylococci are due to Staphylococcus epidermidis.
- β -lactamase production in Staphylococci is under plasmid control.
- Expression of methicillin resistance in Staphylococcus aureus increases when it is incubated at 37°C on blood agar.
- Methicillin resistance in Staphylococcus aureus is independent of β -lactamase production.

Ans 3,

27. All of the following are correct regarding Legionellae except:

- Legionellae can be grown on complex media.
- Legionella pneumophila serogroup 1 is the most common serogroup isolated from humans.

- Legionellae are communicable from infected patients to others.
- Legionella pneumophila is not effectively killed by polymorphonuclear leukocytes.

Ans 3

28. Which of the following is the aetiological agent most often associated with Epiglottitis in children?

- Streptococcus pneumoniae.
- Haemophilus influenzae type B.
- Neisseria sp.
- Moraxella catarrhalis.

Ans 2

29. A 30-year-old male patient presents with urethritis. All of the following can be the causative agent except:

- Neisseria gonorrhoeae.
- Chlamydia trachomatis.
- Trichomonas vaginalis.
- Haemophilus ducreyi.

Ans 4

To remember that H ducreyi ulcers are painful, simply think **H Do CRY** does make you cry!

30. Which one of the following is detected by the antigen detection test used for the diagnosis of P. falciparum malaria?

- Circum-sporozoite protein.
- Merozoite surface antigen.
- Histidine – Rich – Protein I (HRP-I)
- Histidine – Rich – Protein II (HRP - II)

Ans 4, Rapid diagnosis of P. falciparum infection is based on detection of circulating antigen P. falciparum Histidine-rich protein-2 (Pf HRP-2) in whole blood. It is a water soluble protein synthesized by the parasite and released from the P. falciparum infected erythrocytes.

(Also H15th-1208)

31. A 15-year-old girl was admitted to the infectious disease hospital with a provisional diagnosis of rabies. The most suitable clinical sample that can confirm the antemortem diagnosis is:

- Serum for anti-rabies IgG antibody.
- Corneal impression smear for immunofluorescence stain.
- CSF sample for viral culture.
- Giemsa stain on smear prepared from salivary secretions.

Ans 2

32. In a completely and adequately immunized child against Diphtheria, the throat swab was collected. It showed the presence of Corynebacterium diphtheriae like organisms on Albert staining. These organisms can have one of the following properties on further laboratory processing:

- It can grow on Potassium tellurite medium.
- It would show a positive Elek's gel precipitation test.
- It can be pathogenic to experimental guinea pigs.
- It can produce cytotoxicity in tissue cultures.

Ans 1

33. A 35-year-old patient complains of abdominal cramps along with profuse diarrhea. The treating physician wants to process the

AIPPG.com™ AIIMS NOV 2004 released answers, Discuss these at AIPPG.net forums!

stool specimen for isolation of *Campylobacter jejuni*. Which of the following is the method of choice for the culture of stool?

- Culture of TCBS medium incubated at 37°C under aerobic conditions.
- Culture on skirrow's medium incubated at 42°C under micro-aerophilic conditions.
- Culture on Mackconkey's medium incubated at 42°C under anaerobic conditions.
- Culture on Wilson and Blair's medium incubated at 37°C under microaerophilic conditions.

Ans 2

34. Which of the following organisms, when isolated in the blood, requires the synergistic activity of penicillin plus an aminoglycoside for appropriate therapy?
- Enterococcus faecalis*.
 - Staphylococcus aureus*.
 - Streptococcus pneumoniae*.
 - Bacteroides fragilis*.

Ans 1

35. A fourteen year old boy is admitted with history of fever, icterus, conjunctival suffusion and haematuria for twenty days. Which of the following serological test can be of diagnostic utility?
- Widal test
 - Microscopic Agglutination Test
 - Paul Bunnell test
 - Weil felix reaction.

Ans 2, this is a case of leptospirosis. (ictero-hemorrhagic).

36. All of the following are indications for post operative Radiotherapy in a case of Carcinoma Endometrium except:
- Myometrial invasion > ½ thickness.
 - Positive lymph nodes.
 - Endocervical involvement.
 - Tumor positive for estrogen receptors.

Ans 4

37. Use of the following drug to treat hypertension with pregnancy is contraindicated:
- Enalapril
 - Methyldopa
 - Nifedipine
 - Labetolol.

Ans 1

38. All of the following can cause DIC during pregnancy except:
- Diabetes mellitus.
 - Amniotic fluid embolism
 - Intrauterine fetal death
 - Abruptio Placentae.

Ans 1

39. Use of oral contraceptives decreases the incidence of all of the following except:
- Ectopic pregnancy.
 - Epithelial ovarian malignancy.
 - Hepatic adenoma.
 - Pelvic inflammatory disease.

Ans 3 (it increases the incidence of benign and malignant tumours of liver. Also note that incidence of fibrolamellar variant of HCC is NOT increased: Harrison's 16th)

40. A 40-year-old patient is suffering from carotid body tumor. Which of the following is the best choice of treatment for him?
- Surgical excision
 - Radiotherapy
 - Chemotherapy.
 - Carotid artery ligation both proximal and distal to the tumor.

Ans 1, <60 excision, >60 leave as it is. This is a very slowly growing tumour and does not demand removal after 60 as it will grow very slowly.

41. In a young female of reproductive age an absolute contraindication for prescribing oral contraceptive pills is:
- Diabetes.
 - Hypertension
 - Obesity
 - Impaired liver function.

Ans 4

42. All of the following biochemical markers are included for triple test except:
- Alfa feto protein (AFB)
 - Human chorionic gonadotropin (HCG)
 - Human Placental Lactogen (HPL)
 - Unconjugated oestriol.

Ans 3, Human Placental Lactogen (hPL) is also called as human chorionic somatomammotropin (hCS). The important aspect about this is that it disappears from urine / serum even 1 day after delivery. Its peak levels are found at 4 weeks and this is supposed to be growth hormone of pregnancy. Its levels rise after maternal fasting and insulin induced hypoglycemia. Intra amniotic infusion of PGF2 causes marked suppression of hCS levels. It is also called as **PAPP- D (pregnancy associated plasma protein – D)**

What to tell about triple test?

43. In a young female of reproductive age with regular menstrual cycles of 28 days ovulation occurs around 14th day of periods. When is the first polar body extruded:
- 24 hours prior to ovulation.
 - At the time of ovulation.
 - 48 hours after the ovulation
 - At the time of fertilization.

Ans 2, Repeat AIIMS Nov 2003, this actually occurs 6 hours prior to ovulation, Here 2 is the best possible answer.

44. When does switchover from fetal to adult hemoglobin synthesis begin:
- 14 weeks gestation
 - 30 weeks gestation
 - 36 weeks gestation
 - 7 – 10 days postnatal.

Ans 1, note that the question mentions begins.

45. The most common **pure malignant** germ cell tumor of the ovary is:
- Choriocarcinoma.
 - Gonadoblastoma.
 - Dysgerminoma.
 - Malignant teratoma.

Ans 3, There is no doubt about the answer, **dysgerminoma is more common than malignant teratoma**. It is a **pure germ cell** tumour. Though the name sounds so beingn (slow growing) it is **malignant in 100 % of cases**. (Confirmed)

46. During laparoscopy the preferred site for obtaining cultures in a patient with acute pelvic inflammatory disease is:
- Endocervix
 - Pouch of Douglas.
 - Endometrium.
 - Fallopian tubes.

Ans 2

47. The risk of complex hyperplasia of endometrium with atypia progressing to malignancy in a postmenopausal woman is:
- 3%
 - 8%
 - 15%
 - 28%

Ans 4

Question taken from this book, Reference: COGDT 9th Edition, 2003 (Page 918)

Endometrial hyperplasia and their risk of progression to malignancy

Name	Risk of progression to malignancy	Additional points
Simple Hyperplasia without atypia	1 %	Previously called cystic hyperplasia, Glands have a 'Swiss cheese' appearance. Usually asymptomatic and incidental finding at hysterectomy.
Complex hyperplasia without atypia	3 %	Previously called as 'adenomatous hyperplasia'. 85 % have reversal with Progestin therapy. Epithelial stratification may be found
Simple hyperplasia with atypia	8 %	5- 94 % of these regress with progestin therapy but relapse of stopping drug is common. In case of relapse Hysterectomy is recommended. (any route) As atypia suggests nucleus / cytoplasm ratio increased & chromatin clumping , prominent nucleoli are seen.
Complex hyperplasia with atypia	29 %	

48. At 28 weeks gestation, amniocentesis reveals a ΔOD 450 nm of 0.20, which is at the top of third zone of the liley curve. Appropriate management of such a case is:

- Immediate delivery
- Intrauterine transfusion.
- Repeat Amniocentesis after 1 week
- Plasmapheresis.

Ans 2

49. Which of the following is the investigation of choice for assessment of depth of penetration and perirectal nodes in rectal cancer?

- Trans rectal ultrasound.
- CT scan pelvis.
- MRI Scan.
- Double contrast Barium enema.

Ans 1

50. A primigravida presents to casualty at 32 weeks. Gestation with acute pain abdomen for 2 hours, vaginal bleeding and decreased fetal movements. She should be managed by:

- Immediate caesarean section
- Immediate induction of labour
- Tocolytic therapy
- Magnesium sulphate therapy.

Ans 2, Induction of labor is recommended to fetal distress. As per page grading of abruptio this appears to be grade 1. (to confirm)

51. A 15-year-old boy presented with painful swelling over the left shoulder. Radiograph of the shoulder showed and osteolytic area with stippled calcification over the proximal humeral epiphysis. Biopsy of the lesion revealed an immature fibrous matrix with scattered giant cells. Which of the following is the most likely diagnosis?

- Giant Cell Tumor.
- Chondroblastoma
- Osteosarcoma
- Chondromyxoid fibroma

Ans 2. Tumour is located in epiphysis. Common site for Chondromyxoid fibroma is metaphysical.

Always go for cartilaginous tumours when you see "**stippled calcification**"

52. A 46-year-old, known alcoholic, presented with pain in the dorsal spine. On examination there is tenderness at the dorso-lumbar junction. Radiograph shows destruction of the 12th dorsal vertebra with loss of disc space between D₁₂-L₁ vertebrae. The most probable diagnosis is:

- Metastatic spine disease.
- Pott's spine
- Missed trauma.
- Multiple myeloma.

Ans 2, Missed trauma wont lead to destruction of vertebrae and loss of joint space.

53. A 50-year-old man sustained posterior dislocation of left hip in an accident. Dislocation was reduced after 3 days. He started complaining of pain in left hip after 6 months. X-rays of the pelvis

were normal. The most relevant investigation at this stage will be:

- CRP levels in blood.
- Ultrasonography of hip
- Arthrography of hip
- MRI of hip.

Ans 4, this is a typical case of AVN, whose early diagnosis is done by MRI.

Remember that "crescent" sign in X ray is found in AVN. Also avascular necrosis is a favorite topic of All India and AIIMS, repeated in different so called clinical themes.

54. A one and a half year old child holding her father's hand slipped and fell but did not let go of her father's hand. After that, she continued to cry and hold the forearm in pronated position and refused to move the affected extremity. Which of the following management at this stage is most appropriate?
- Supinate the forearm.
 - Examine the child under GA.
 - Elevate the limb and observe.
 - Investigate for osteomyelitis.

Ans 1, This is a case of pulled elbow. Here following findings are present (also called as nursemaid elbow)

Physical:

- Physical examination commonly reveals an anxious child who is protective of the affected arm.
- In most children, anxiety is greater than pain.
- The forearm is usually flexed 15-20 degrees at the elbow and the forearm partially pronated.
- Often the weight of the affected arm is supported with the other hand.
- Erythema, warmth, edema, or signs of trauma are absent.
- Distal circulation, sensation, and motor activity are normal. A reluctance to move digits or the wrist is common, probably from fear of eliciting pain in the elbow.
- Tenderness at the head of the radius may be present.
- The patient resists supination/pronation as well as flexion/extension of the forearm.

Treatment: consists of manipulating the child's arm so that the annular ligament and radial head return to their normal anatomical positions.

- This is accomplished by immobilizing the elbow and palpating the region of the radial head with one hand.
- The other hand applies axial compression at the wrist while supinating the forearm and flexing the elbow.
- As the arm is manipulated, a click or snap can be felt at the radial head.

55. A 30-year-old man involved in a fistcuff, injured his middle finger and noticed slight flexion of DIP joint. X-rays were normal. The most appropriate management at this stage is:
- Ignore
 - Splint the finger in hyperextension
 - Surgical repair of the flexor tendon.
 - Buddy strapping.

Ans 2, This is a case of mallet finger, and here a splint is used to hold the finger in hyperextension. Choice 4 hyper extension is used in fracture of shaft of phalanges.

56. Ebstein Barr virus is associated with:
- Carcinoma larynx
 - Carcinoma bladder.
 - Carcinoma nasopharynx.
 - Carcinoma Maxilla.

Ans 3

57. The type of Allergic reaction seen in Allergic fungal sinusitis is:
- Type 1 and Type 2
 - Type 2 and Type 3
 - Type 1 and Type 3
 - Type 4 and Type 1

Ans 3, (Update),

Currently, the pathophysiology of Allergic Fungal Sinusitis is postulated to be similar to that of allergic bronchopulmonary fungal disease (a term replacing bronchopulmonary aspergillosis). An initial inflammatory response ensues as the result of both a Gell and Coombs type I (IgE-mediated) and type III (immune complex-mediated) reaction, causing subsequent tissue edema.

A diagnosis of Allergic fungal sinusitis is suspected when person does not show any response to two antibiotic courses of 3 weeks. Calcification is also suggestive.

Hypersensitivity diseases of the lungs may be caused by more than one type of hypersensitivity reaction. For example Hypersensitivity pneumonitis may involve types III and IV; Allergic bronchopulmonary aspergillosis, types I and III.

58. Calcification of soft tissues without any disturbance of calcium metabolism is called:
- Ionotrophic calcification.
 - Monotrophic calcification.
 - Dystrophic calcification.
 - Calcium induced calcification.

Ans 3

59. All of the following techniques are used to control bleeding from bone during mastoid surgery except:
- Cutting drill over the bleeding area.
 - Diamond drill over the bleeding area.
 - Bipolar cautery over the bleeding area.
 - Bone wax.

Ans 1, Bone wax is typically used to control bleeding from Bony surfaces. Drills are used to open bone to expose mastoid bone.

Bipolar coagulation is the cautery method of choice in CNS surgery as unipolar injures nerves, may increase V3 and cause cardiac arrhythmias. (UNIPOLAR is NEVER used near any nerves specially facial here)

Also General surgical technique of mastoid involves the use of diamond-tipped burrs of various sizes.

60. To prevent synechiae formation after nasal surgery, which one of the following packings is the most useful:
- Mitomycin.
 - Ribbon gauze.
 - Ribbon gauze with liquid paraffin.
 - Ribbon gauze steroids.

Ans 3

61. A 2 month old girl has failure to thrive, polyuria and medullary nephrocalcinosis affecting both kidneys. Investigations show blood pH 7.48, bicarbonate 25 mEq/l, potassium 2 mEq/l, sodium 126 mEq/l and chloride 88 Eq/l. The most likely diagnosis is:
- Distal renal tubular acidosis.
 - Primary hyperaldosteronism
 - Bartter syndrome
 - Pseudohypoaldosteronism.

Ans 3

62. A 3-year-old boy has bilateral renal calculi secondary to idiopathic hypercalciuria. The dietary management includes all of the following except:
- Increased water intake.
 - Low sodium diet.
 - Reduced calcium intake
 - Avoidance of meat proteins.

Ans 3, This answer is contrary to Nelson 17th edition and CMDT 2004. Both of which say that calcium reduction is necessary.

But Harrison (16th ed) wrote that in a controlled trial it was found that calcium restriction lead to decreased bone growth / osteoporosis and INCREASED incidence of urinary stones. This trial recommended decreased protein, sodium and increased water, increased citrate diet. Citrate keeps more calcium in dissolved form. According to Harrison (15 / 16th any) the distinction of Idiopathic hypercalciuria into Absorptive, resorptive and renal is not useful and no longer made!

63. A 9-year-old boy has steroid dependent nephritic syndrome for the last 5 years. The patient is markedly cushingoid with blood pressure of 120/86 mmHg and small subcapsular cataracts. The most appropriate therapy of choice is:
- Longterm frusemide with enalapril.
 - Cyclophosphamide.
 - Intravenous immunoglobulin.
 - Intravenous pulse corticosteroids.

Ans 2, Steroid dependent nephritic syndrome developing side effects of corticosteroids: Give immunosuppressant

64. An 8 day old breast fed baby presents with vomiting, poor feeding and loose stools. On examination the heart rate is 190/minute, blood pressure 50/30 mm Hg, respiratory rate 72 breaths/minute and capillary refill time of 4 seconds. Investigation show hemoglobin level of 15 mEq/l, urea 30 mg/dL and creatinine 0.6 mg/dL. The most likely diagnosis is:
- Congenital adrenal hyperplasia.
 - Acute tubular necrosis.
 - Congenital hypertrophic pyloric stenosis.
 - Renal tubular acidosis.

Ans 1, This is repeat from AIIMS nov 2003, This is classic salt wasting form of CAH which presents as salt losing nephropathy around 8-10 days, it is NOT ATN (choice 2) as creatinine is normal.

65. A 2-year-old child is being evaluated for persistent metabolic acidosis. Blood tests show Na⁺ 140 mEq/L, Ca²⁺ 8mg/dL, Mg²⁺ 2 mg/dL, phosphate 3 mg/dl, pH 7.22, bicarbonate 16 mEq/l and chloride 112 mEq/l. The plasma anion gap is:

- 9
- 15
- 22
- 25

Ans 2, [Na + K] - [Hco₃ + Cl]

Why I would not include Ca²⁺ 8mg/dL, Mg²⁺ 2 mg/dL, phosphate 3 mg/dl? As these values are in Mg/dL. I don't think so that AIIMS people wanted you to make conversion of Mg/dL into mEq/L.

66. A child underwent a tonsillectomy at 6 years of age with no complications. He underwent a preoperative screening for bleeding at the age of 12 years before an elective laparotomy, and was found to have a prolonged partial thromboplastin time but normal prothrombin time. There was no family history of bleeding. The patient is likely to have:
- Acquired vitamin K deficiency.
 - Acquired liver disease.
 - Factor XII deficiency.
 - Mild hemophilia A

Ans 3, note that FACTOR XII and XIII deficiency do not cause any problems except for slightly prolonger PTT, More updates later.

67. A child presents with peripheral circulatory failure. The arterial pH is 7.0. pCO₂ of 15 mmHg. pO₂ 76 mm Hg. Which of the following will be the immediate therapy?
- Sodium bicarbonate infusion
 - Bolus of Ringers lactate.
 - Bolus of hydroxyethyl starch.
 - Dopamine infusion

Ans 2, Most of his acidosis will do away when circulatory failure is improved, The first priority is establishing circulation as in ABC. The person is in shock.

68. A 5-year-old child is rushed to casualty reportedly electrocuted while playing in a park. The child is apneic and is ventilated with bag and a mask. Which of the following will be the next step in the management
- Check pulses
 - Start chest compression
 - Intubate
 - Check oxygen saturation

Ans 1, for those who want to vote for 4 Intubation, let me tell you that bag and mask ventilation is an equivalent of mouth to mouth respiration in basic life support. It is used if it is available & at least 2 rescuers are present

Also the ABC rule is followed without fail in any emergency without fail!

69. A 12-year-old girl has history of recurrent bulky stools and abdominal pain since 3 years of age. She has moderate pallor and her weight and height are below the 3rd percentile. Which of the following is the most appropriate investigation to make a specific diagnosis?
- Small intestinal biopsy
 - Barium studies
 - 24-hours fecal fat estimation.
 - Urinary d-xylose test.

AIPPG.com™ AIIMS NOV 2004 released answers, Discuss these at AIPPG.net forums!

Ans 1, 24 hr fecal fat estimation, is a non specific test. You cannot diagnose any specific thing with this test. (any of the malabsorption syndromes)
But with Small intestinal biopsy you can diagnose accurately Coeliac ds, Whipples disease accurately if not more.

Related: Coeliac crisis manifests as diarrhea, weight loss, hypocalcemia, hypoproteinemia and is treated with corticosteroids.

70. The treatment of choice for primary grade V vesicoureteric reflux involving both kidneys in a 6 months old boy is:
- Antibiotic prophylaxis
 - Ureteric reimplantation.
 - Cystoscopy followed by subureteric injection of Teflon.
 - Bilateral ureterostomies.

Ans 1, see [Nelson table copied in this forum post by AIPPG](#) (17th latest edition)

TABLE 531-2. Treatment Recommendations for Vesicoureteral Reflux Diagnosed Following a Urinary Tract Infection*

Grade	Age (yr)	Scarring	Initial Treatment	Follow-up
I-II	Any	Yes/no	Antibiotic prophylaxis	No consensus
III-IV	0-5	Yes/no	Antibiotic prophylaxis	Surgery
III-IV	6-10	Yes/no	Unilateral: antibiotic prophylaxis Bilateral: surgery	Surgery
V	<1	Yes/no	Antibiotic prophylaxis	Surgery
V	1-5	No	Unilateral: antibiotic prophylaxis Bilateral: surgery	Surgery
V	1-5	Yes*	Surgery	
V	6-10	Yes/no	Surgery	

Handwritten notes: TMF → MS → 1st 2 months; Surgery; Caplin; Lexin; ADX

71. The most common causative organism for lobar pneumonia is:
- Staphylococcus aureus*.
 - Streptococcus pyogenes*.
 - Streptococcus pneumoniae*
 - Haemophilus influenzae*

Ans 3, Pneumonia > H Influenzae > Morexella (PIM)

72. All of the following clinicopathologic features are seen more often in seminomas as compared to non-seminomatous germ cell tumors of the testis, except:
- Tumors remain localized to testis for a long time.
 - They are radiosensitive
 - They metastasize predominantly by lymphatics.
 - They are often associated with raised levels of serum alpha-feto protein and human chorionic gonadotrophin.

Ans 4.

73. All of the following statements are true regarding central nervous system infections. Except:
- Measles virus is the causative agent for subacute sclerosing pan encephalitis (SSPE)
 - Cytomegalovirus causes bilateral temporal lobe hemorrhagic infarction.
 - Prions infections causes spongiform encephalopathy.

- JV virus is the causative agent for progressive multifocal leucoencephalopathy.

Ans 2, HSV causes bilateral temporal lobe hemorrhagic infarction; NOT CMV.

74. HIV associated nephropathy is a type of:
- Membranous glomerulonephritis.
 - Immunotactoid glomerulopathy.
 - Collapsing glomerulopathy.
 - Fibrillary glomerulopathy.

Ans 3, Actually HIV infection causes FSGS (focal sclerosing glomerulosclerosis) but the difference with normal FSGS is that here capillary tufts are collapsed. (harrison) So the answer is 3. No other reference.

75. Ladder pattern of DNA electrophoresis in apoptosis is caused by the action of the following enzyme:
- Endonuclease .
 - Transglutaminase.
 - DNase.
 - Caspase.

Ans 1.

76. Which one of the following is not a criterion for making a diagnosis of chronic myeloid leukemia in accelerated phase:
- Blasts 10-19% of WBC's in peripheral blood.
 - Basophils 10-19% of WBC's in peripheral blood.
 - Increasing spleen size unresponsive to therapy,
 - Persistent thrombocytosis (>1000 x 10⁹ /L) unresponsive to therapy.

Ans 2, Basophils should be greater than 20 % for a diagnosis of Accelerated CML.

- Accelerated CML requires one of the following to be present: **Blasts comprising 10 to 19% of the peripheral blood WBCs and/or of nucleated bone marrow cells**
- ≥20% peripheral blood basophils**
- Persistent thrombocytopenia (<100 x 10⁹/L) unrelated to treatment
- Persistent thrombocytosis (>1000 x 10⁹/L) unresponsive to treatment
- Increasing splenomegaly or leukocytosis unresponsive to treatment
- Cytogenetic evidence of clonal evolution

This is different from BLAST phase where the following are required for diagnosis

- Blasts composing ≥20% of peripheral blood WBCs or of nucleated bone marrow cells
- Extramedullary blast proliferation
- Large foci or clusters of blasts in the bone marrow biopsy

[With thanks from Vardiman JW, et al. Chronic myeloproliferative diseases and Myelodysplastic/myeloproliferative diseases. In: Jaffe ES, Harris NL, Stein H, Vardiman JW, eds. World Health Organization Classification of Tumours. Pathology and Genetics. Tumours of Haematopoietic and Lymphoid Tissues. Lyon, France: IARC Press, 2001:17-31,47-52.]

77. CD 19 positive, CD 22 positive, CD 103 positive monoclonal B-cell with bright kappa positivity were found to comprise 60% of

the peripheral blood lymphoid cells on flow cytometric analysis in a 55 year old man with massive splenomegaly and a total leucocyte count of $3.3 \times 10^9/L$. Which one of the following is the most likely diagnosis?

- Splenic lymphoma with villous lymphocytes.
- Mantle cell lymphoma.
- B-cell prolymphocytic leukemia.
- hairy cell leukemia

Ans.4. (CD 103 +ve, 55 years, B cells)

78. A four year old boy was admitted with a history of abdominal pain and fever for two months, maculopapular rash for ten days, and dry cough, dyspnea and wheezing for three days. On examination, liver and spleen were enlarged 4 cm and 3 cm respectively below the costal margins. His hemoglobin was 10.0 g/dl, platelet count $37 \times 10^9/L$ and total leukocyte count $70 \times 10^9/L$, which included 80% eosinophils. Bone marrow examination revealed a cellular marrow comprising 45% blasts and 34% Eosinophils and eosinophilic precursors. The blasts stained negative for myeloperoxidase and non specific esterase and were positive for CD19, CD10, CD22 and CD20.

Which one of the following is the most likely diagnosis?

- Biphenotypic acute leukemia (lymphoid and eosinophil lineage).
- Acute eosinophilic leukemia.
- Acute lymphoblastic leukemia with hypereosinophilic syndrome.
- Acute myeloid leukemia with eosinophilia.

Ans 3, This is taken from a case report published by one of AIIMS doctors in 2000. One or two of these type questions are always there, we are always wise afterwards about them.

Below is abstract of that patient case report, the patient mentioned in the questions matched the patient here ditto.

Granular acute lymphoblastic leukemia with hypereosinophilic syndrome.

Jain P, Kumar R, Gujral S, Kumar A, Singh A, Jain Y, Dubey S, Anand M, Arya LS.

Unit of Laboratory Oncology, Institute Rotary Cancer Hospital, All India Institute of Medical Sciences, New Delhi, India.
pareshjain@hotmail.com

A four-year-old boy presented with marked peripheral blood eosinophilia (absolute eosinophil count of $54 \times 10^9/L$), features of hypereosinophilic syndrome, and acute lymphoblastic leukemia (ALL-L2), the latter characterized by the presence of granular blasts. Blasts were negative for myeloperoxidase, non-specific esterase, acid phosphatase, periodic-acid Schiff stain, and toluidine blue. They exhibited an early pre-B immunophenotype (TdT, CD19, CD10, CD20 and CD22 positive) and stained negative for T (CD7, CD2, CD5 and CD3) and myeloid markers (MPO, CD33 and CD13). Chromosomal analysis revealed a normal karyotype. To the best of our knowledge, this case represents the first report of the coexistence of granular ALL and hypereosinophilic syndrome. See this thread [click here](#) **Very sure]**

<http://www.aippg.net/forum/viewtopic.php?p=31143#31143>

AIPPG.com

79. All of the following are examples of tumor markers, except:
- Alpha – HCG (α -HCG).
 - Alpha – Feto Protein.
 - Thyroglobulin.
 - β_2 – microglobulin.

Ans 1, Alpha HCG [The problem here is that all 4 are tumour markers > PROVED for sure. Alpha HCG is a marker for Zollinger Ellison syndrome (Ref CSDT).

Thyroglobulin is a marker of thyroid cancer.

β_2 – microglobulin has been proven to be a tumour marker for space occupying lesions of central nervous system, multiple myeloma (single most important prognostic indicator) , to a lesser extent with stage III and IV ovarian cancers, oral cancers..

I wont comment on Alpha – Feto Protein!! In my belief 1 is the best answer. But it is either 1 or 3

80. Which of the following combination of cytogenetic abnormality and associated leukemia / lymphoma is incorrect?
- t(8:14)Burkitts lymphoma.
 - t(15:17)AML – M3.
 - t(9:22)CML.
 - t(9:20)ALL.

Ans 4

81. Endoscopic biopsy from a case of H. Pylori related duodenal ulcer is most likely to reveal:
- Antral predominant gastritis.
 - Multifocal atrophic gastritis.
 - Acute erosive gastritis.
 - Gastric atrophy.

Ans 1

H pylori causes two types of gastritis:

- Antral predominant: Associated with duodenal ulcer** and higher acid production. Here interleukin 1 β production is low
- Multifocal atrophic : Associated with **lower gastric acid production and higher risk of adenocarcinoma**. Here interleukin 1 β production is High.

Reference: Page 814 Robbins7th ed.

82. Early gastric cancer generally indicates:
- Gastric adenocarcinoma detected early.
 - Gastric adenocarcinoma confined to the mucosa
 - Gastric adenocarcinoma confined to the mucosa and submucosa.
 - Gastric adenocarcinoma less than 1 cm. In size.

Ans 3

83. A neonate is being investigated for jaundice. A liver biopsy shows features of a "Giant Cell/ Neonatal hepatitis". Which one of the following conditions usually results in this case?
- Congenital hepatic fibrosis.

- b. Hemochromatosis.
- c. Alpha-1-antitrypsin deficiency.
- d. Glycogen storage disease Type 1

Ans 3, this is more common than choice 1. Also Nelson says that histological feature of Alpha -1 antitrypsin deficiency is same as Neonatal hepatitis (giant cells), it presents as jaundice, hepatomegaly during 1st week of life.

84. A 20-year-old male has presented with repeated episodes of hematemesis. There is no history of jaundice or liver decompensation. On examination the significant findings include splenomegaly (8 cms below costal margin). And presence of esophageal varices. There is no ascites or peptic ulceration. The liver function tests are normal. The most likely diagnosis is:
- a. Extrahepatic portal venous obstruction
 - b. Non cirrhotic portal fibrosis.
 - c. Cirrhosis.
 - d. Hepatic venous outflow tract obstruction.

Ans 1

85. A male infant presented with distension of abdomen shortly after birth with passing of less meconium. Subsequently a full-thickness biopsy of the rectum was performed. The rectal biopsy is likely to show:
- a. Fibrosis of submucosa.
 - b. Lack of ganglion cells
 - c. Thickened muscularis propria.
 - d. Hyalinisation of the muscular coat.

Ans 2 (hirschsprung disease)

86. Women receiving oestrogen therapy have an increased risk of developing all of the following cancers, except:
- a. Breast cancer.
 - b. Endometrial carcinoma
 - c. Carcinoma of gall bladder
 - d. Hepatocellular carcinoma

Ans 3, Harrison writes that OCP's may lead

87. All of the following disease cause massive splenomegaly except:
- a. Malaria
 - b. Kalrazar
 - c. Lymphoblastic leukaemia
 - d. Idiopathic myelofibrosis.

Ans 3

88. A 48-year-old woman was admitted with a history of weakness for two months. On examination, cervical lymph nodes were found enlarged and spleen was palpable 2 cm below the costal margin. Her hemoglobin was 10.5 g/dl, platelet count $237 \times 10^9 / L$ and total leukocyte count $40 \times 10^9 / L$, which included 80% mature lymphoid cells with coarse clumped chromatin. Bone marrow revealed a nodular lymphoid cells were positive for CD19,CD5, CD20 and CD23 and were negative for CD79B and FMC -7.

Which one of the following statements is not true about this disease?

- a. Trisomy 12 correlates an aggressive clinical course.
- b. Abnormalities of 13q14 are associated with long term survival

- c. Cases with 11q22-23 deletions have excessive lymphadenopathy.
- d. T(11;14) translocation is present in most of the cases.

Ans 4

The answer is 4

The point is the presence of CD5 and CD23 which points towards a diagnosis of CLL/SLL. Also please refer Harrison that trisomy 12 and defects in chromosome 13 can be seen in CLL.

t(11;14) is seen typically in mantle cell lymphoma where bcl1 is the main defect.

Mantle cell lymphoma	Follicular lymphoma	Hairy cell lymphoma
CD 5 +ve CD 23 -ve	CD5 -ve CD 23 +ve (Follicular is Five negative)	CD 5 +ve & CD 23 +ve

[Dr Suganya, Chennai, Via Forum] [Link : CLL](#)

Cell	CD	Important points
T Cell	CD1,CD2,CD3,CD4, CD5,CD7,CD8	1-8 EXCEPT 6
B Cell	CD10,CD19,CD20 ,CD21,CD22,CD23	10,19-23
Macrophage, Monocyte	CD13,CD14,CD15,CD33	13-15,33
NK Cell	CD16,CD56	16,56

89. All of the following statements are incorrect about the treatment of prolonged suxamethonium apnea due to plasma cholinesterase deficiency (After a single dose of suxamethonium) except:
- a. Reversal with incremental doses of neostigmine
 - b. Continue anesthesia and mechanical ventilation till recovery.
 - c. Transfusion of fresh frozen plasma.
 - d. Plasmapheresis.

Ans 3

There are three types of plasma cholinesterase induced toxicity in those who are given Suxamethonium.

- 1) Type 1 Plasma pseudo cholinesterase deficient : Give Fresh frozen Plasma.
- 2) Type 2 Abnormal Plasma pseudo cholinesterase give IPPV
- 3) Type 3 also give IPPV

Ref Ajay Yadav, A short text book of Anaesthesia.

90. The operating temperature in an ethylene oxide sterilization during a warm cycle is:
- a. 20-35 °C.
 - b. 49-63 °C
 - c. 68-88 °C
 - d. 92-110 °C

Ans 2 [see this [forum post](#),]

Answer is b. Though ETO is explosive at temperatures above room temp., it is kept in an atmosphere of CO2 to prevent its

explosion and the warm cycle is maintained at @ 55°C . [Dr Suganya, Chennai]

91. Which of the following does not represent a significant anaesthetic problem in the morbidly obese patient?
- Difficulties in endotracheal intubation.
 - Suboptimal arterial oxygen tension.
 - Increased metabolism of volatile agents.
 - Decreased cardiac output relative to total body mass.

Ans 3?

92. A 6-month old child with tetralogy of Fallot develops cyanotic spell initiated by crying. Which one of the following drugs you would like to avoid?
- Sodium bicarbonate.
 - Propranolol
 - Phenylephrine.
 - Isoprenaline.

Ans 4, Ref Ghai.

Treatment of anoxic spells in TOF in order

- Place in Knee chest position
 - O₂
 - Morphine
 - Sodium Bicarbonate
 - Beta Blocker
 - Increase peripheral resistance by phenylephrine etc.
93. A 10-days old neonate is posted for pyloric stenosis surgery. The investigation report shows a serum calcium level of 6.0 mg/dl. What information would you like to know before you supplement calcium to this neonate?
- Blood glucose.
 - Serum protein.
 - Serum bilirubin
 - Oxygen saturation.

Ans 2, Harrison says that with each gram decrease in protein in plasma: ADD 1 to the estimated calcium level for the purpose of establishing effective calcium levels. Also (below) 8 Mg/ DL is a critical level

94. A 20-year-old female weighing about 55 kg is admitted to an emergency department having consumed 10 g of paracetamol (acetaminophen) together with alcohol, 6 hours earlier. A serum paracetamol level is reported as 400 micrograms/ml. Which one of the following is correct in this case?
- Gastric lavage is mandatory.
 - Administration of activated charcoal.
 - Abnormalities of kidney function are likely to be present.
 - Hepatotoxicity is likely to occur.

Ans 4

95. An unconscious man is brought into hospital suffering from methyl alcohol poisoning. All of the following are correct except:
- Kussmaul's breathing could be expected to be a feature of the condition.
 - Papilloedema would be consistent with this form of intoxication.
 - His plasma bicarbonate might be very low
 - Methyl alcohol would be metabolized to acetaldehyde.

Ans 4

96. All of the following for managing status epilepticus except
- Phenytoin
 - Diazepam
 - Thiopentone sodium
 - Carbamazepine

Ans 4

97. A patient following head injury was admitted in intensive care ward with signs of raised intracranial pressure. He was put on ventilator and started on intravenous fluids and diuretics. Twenty four hours later his urine output was 3.5 liter, serum sodium 156 mEq/l and serum osmolarity of 316 mOsm/kg. The most likely diagnosis based on these parameters is
- High output due to diuretics
 - Diabetes insipidus
 - Too much infusion of normal saline
 - Cerebral salt retaining syndrome

Ans 2/4? To confirm.

98. Which one of the following statements regarding desflurane is correct
- It causes severe myocardial depression
 - It is structural analogue of isoflurane
 - It has very high blood and tissue – gas partition coefficients
 - It is metabolically unstable

Ans 2, Reference Ajay Yadav "A short textbook of Anaesthesia"Page 62.

99. A 52-year-old male diagnosed as triple vessel coronary artery disease with poor left ventricular function. Coronary artery bypass grafting surgery maintenance of anaesthesia which one of the following agents should be preferred
- IV Opioids
 - Isoflurane
 - Halothane
 - Nitrous oxide

Ans 4, Ref Ajay Yadav

100. Trendelenberg position produces decreases in all of the following except
- Vital capacity
 - Functional residual capacity
 - Compliance
 - Respiratory rate

Ans 4, RR is increased. Vital capacity falls by 15 %.

Changes in Trendelenberg position:

- CVP : ?
- ICT : ?
- IOT: ?
- Myocardial work: ?**
- FRC ?**
- VC ?**

101. Urgent reversal of Warfarin therapy can be done by administration of
- Cryoprecipitates
 - Platelet concentrates

- c. Fresh frozen plasma
- d. Packed red blood cell

Ans 3

102. All of the following drugs are eliminated by kidney except

- a. Pancuronium bromide
- b. Atracurium besylate
- c. Vecuronium bromide
- d. Pipecuronium

Ans 2 (Hoffman's elimination)

103. Which one of the following opioids has maximum plasma protein binding capacity

- a. Morphine
- b. Sufentanil
- c. Fentanyl
- d. Pethidine

Ans 2, Sulfentanil has >90 % plasma protein binding while morphine has only 33 %. Fentanyl has 88 % binding while Sulfentanil has 64 % binding.

104. In computed tomography (CT), the attenuation values are measured in Hounsfield units (HU). At attenuation value of '0' (zero) HU corresponds to

- a. Water
- b. Air
- c. Very dense bone structures
- d. Fat

Ans 1

Water = 0

Air = - 1000

Bone = + 1000

Fat = - 50

Simply remember that fat is lighter than water so will be more negative than water.

105. The EEG cabins should be completely shielded by a continuous sheet of wire mesh of copper to avoid the picking up of noise from external electromagnetic disturbances. Such a shielding is called as

- a. Maxwell cage
- b. Faraday cage
- c. Edison's cage
- d. Ohms cage

Ans 2

106. Which one of the following phenomena is closely associated with slow wave sleep

- a. Dreaming
- b. Atonia
- c. Sleep walking
- d. Irregular heart rate

Ans 3

107. If a single spinal nerve is cut, the area of tactile loss is always greater than the area of loss of painful sensations, because

- a. Tactile information is carried by myelinated fast conducting fibres
- b. Tactile receptors adapt quickly

- c. Degree of overlap of fibres carrying tactile sensation is much less

- d. In the primary sensory cortex tactile sensation is represented on a larger area

Ans 3

108. Massage and the application of liniments to painful areas in the body relieves pain due to

- a. Stimulation of endogenous analgesic system
- b. Release of endorphins by the first order neurons in the brain stem
- c. Release of glutamate and substance P in the spinal cord
- d. Inhibition by large myelinated afferent fibres

Ans 4

109. One of the following statements about hydralazine is not true

- a. It causes direct relaxation of blood vessels
- b. It causes dilatation of both arteries and veins
- c. Postural hypotension is not a common problem
- d. It increases plasma rennin activity

Ans 2

110. One of the following diuretics does not require its presence in the tubular lumen for its pharmacological effects

- a. Thiazide diuretics
- b. Loop diuretics
- c. Carbonic anhydrase inhibitors
- d. Aldosterone antagonists

Ans 4

111. Many of our bad habits of day to day life can be removed by

- a. Positive conditioning
- b. Biofeedback
- c. Negative conditioning
- d. Generalization

Ans 2

I would outline what data I have

Biofeedback training teaches how to consciously change and control the body's vital functions that are normally unconscious, such as breathing, heart rate, and blood pressure, through information provided by electronic devices.

Conditions Treated by Biofeedback

Biofeedback is particularly useful with can help with stress-related conditions where there is sympathetic or adrenal stress.

It is also useful for conditions where there is inadequate control over muscle groups or muscle dysfunction. Conditions treated with biofeedback include:

- stress
- headaches
- asthma
- muscle injury
- pain relief
- insomnia
- TMJ
- high blood pressure

- digestive disorders
- attention deficit disorder
- incontinence
- poor posture
- tennis elbow
- golfer's elbow
- irritable bowel syndrome
- hyperactivity
- Raynaud's disease
- ringing of the ears
- constipation
- twitching of the eyelids
- esophageal dysfunction

This list also includes some day to day problems like insomnia , high BO, poor posture etc.

About Negative conditioning : this is typically used to treat pedophilic in western countries. I doubt if that is a day to day bad habit. Also DO think that this includes punishment given to children for anything habitual.

About positive feedback: this includes giving a reward for good behaviour, personally I don't feel this to be a viable option as person becomes dependent on reward and expects a reward every time for not being BAD!

[NOT RELATED TO THIS Q Finally I believe that BAD and GOOD are relative terms, what is good for someone may be BAD for others]

112. A 30-year-old unmarried woman of average socio – economic background believes that her boss is secretly in love with her. She rings him up to odd hours and writes love letters to him despite his serious warning not to do so. She holds this belief despite contradiction from her family members and his denial. However, she is able to manage her daily activities as before. She is most likely to be suffering from
- a. Depression
 - b. Schizophrenia
 - c. Delusional disorder
 - d. No psychiatric ailment

Ans 3, This is Clérambault syndrome.

113. A 35-year-old male, with pre – morbid anxious traits and heavy smoker, believes that he has been suffering from 'lung carcinoma' for a year. No significant clinical finding is detected on examination and relevant investigations. **He continues to stick to his belief despite evidence to the contrary.** In the process, he has spent a huge amount of money, time and energy in getting himself unduly investigated. He is most likely suffering from
- a. Carcinoma lung
 - b. Delusional disorder
 - c. Hypochondriacal disorder
 - d. Malingering

Ans 3

The answer is Hypochondriasis as

Hypochondriasis involves the following psychopathologies

- 1) Hallucination
- 2) Secondary Delusion
- 3) Primary Delusion
- 4) Overvalued Idea
- 5) Obsessional rumination
- 6) Depressive rumination
- 7) Anxious Preoccupation

Also in ICD-10 classification

Hypochondriasis is defined as

F45-2 : For a definitive diagnosis both of the following should be present

a) Persistent belief in the presence of at least one serious physical illness underlying the presenting symptom (s), even though repeated investigations have identified no physical explanation, or a physical preoccupation with a presumed deformity or disfigurement.

b) Persistent refusal to accept the advice and reassurance of several different doctors that there is no physical illness or abnormality underlying the symptoms

So I believe that the answer is HYPOCHONDRIASIS, Delusion may be present in psychopathology of this disorder.

Hope this rests all confusion

This text was taken from Andrew Sims, Symptoms in the Mind, 3rd edition, which is a beautiful book for psychiatry MD trainees!

114. A 14-year-old has difficulty in expressing himself in writing, and makes frequent spelling mistakes. He passes his examinations with poor marks. However, his mathematical ability and social adjustment are appropriate for his age. Which of the following is the most likely diagnosis
- a. Mental retardation
 - b. Lack of interest in studies
 - c. Specific learning disability
 - d. Examination anxiety
- Ans 3, This is Dyslexia.

115. A 35-year-old man with an obsessive compulsive personality disorder likely to exhibit of the following features, except
- a. Perfectionism interfering with performance
 - b. Compulsive checking behaviour
 - c. Preoccupation with rule
 - d. Indecisiveness

Ans 2, Indecisiveness is seen in OCP, This question tests your ability to differentiate between OC personality and obsessive compulsive neurosis.

116. Which one of the following organs should always be imaged in a suspected case of bronchogenic carcinoma
- a. Adrenals
 - b. Kidneys

- c. Spleen
- d. Pancreas

Ans 1

117. A middle aged man presents with progressive atrophy and weakness of hands & forearms. On examination he is found to have slight spasticity of the legs, generalized hyper – reflexia and increased signal in the cortico – spinal tracts on T2 weighted MRI. The most likely diagnosis is
- a. Multiple sclerosis
 - b. Amyotrophic lateral sclerosis
 - c. Subacute combined degeneration
 - d. Progressive spinal muscular atrophy

Ans 2

118. A 6-year-old boy has been complaining of headache, ignoring to see the objects on the sides for four months. On examination, he is not mentally retarded, his grades at school are good, and visual acuity is diminished in both the eyes. Visual charting showed significant field defect. CT scan of the head showed suprasellar mass with calcification. Which of the following is the most probable diagnosis
- a. Astrocytoma
 - b. Craniopharyngioma
 - c. Pituitary adenoma
 - d. Meningioma

Ans 2

119. Which of the following is the incorrect statement regarding GI Bleeding
- a. The sensitivity of angiography for detecting GI bleeding is about 10-20% as compared to Nuclear Imaging
 - b. Angiography can image bleeding at a rate of 0.05 – 0.1/min or less
 - c. ^{99m}Tc-RBC scan will image bleeding at rates as low as 0.05 – 0.1 ml/min
 - d. Angiography will detect bleeding only if extravasation is occurring during the injection of contrast

Ans 2, **Angiography can image bleeding at a rate of 0.5 ml or MORE**

120. Which one of the following hepatic lesions can be diagnosed with high accuracy by using nuclear imaging
- a. Hepatocellular Carcinoma
 - b. Hepatic Adenoma
 - c. Focal Nodular Hyperplasia
 - d. Cholangiocarcinoma

Ans 3, FNH is best imaged by Nuclear magnetic resonance imaging (MRI), ref Harrison

121. Which one of the following is the most beneficial technique of using chemotherapy with a course of radiotherapy in head and neck malignancies
- a. Neo adjuvant chemotherapy
 - b. Adjuvant chemotherapy
 - c. Concurrent chemotherapy
 - d. Alternating chemotherapy and radiotherapy

Ans 3, Harrison says that because Head and neck cells are so radioresistant, concurrent is more effective, it even obliterates

need for surgery or provides better palliation. Example it may prevent the need for laryngectomy in Ca larynx. Ref 505 Harrison 16th.

122. The treatment of choice in renal cell carcinoma with the tumor of less than 4 cm in size is
- a. Partial nephrectomy
 - b. Radical nephrectomy
 - c. Radical nephrectomy + post operative radiotherapy
 - d. Radical nephrectomy + chemotherapy

Ans 1, Less than 4 cms Rx is Partial Nephrectomy.

According to CSDT indications of partial Nephrectomy are i) tumour less than 4 cms

ii) Diabetes mellitus

iii) Renal cell Ca in solitary kidney.

123. A 7-year-old boy with left renal mass had bone pain was detected to have bone metastatic deposits. The most likely renal tumor is
- a. Favorable histology Wilms tumor
 - b. Renal cell carcinoma
 - c. Clear cell sarcoma
 - d. Rhabdoid tumor

Ans 3, Clear cell sarcoma is a variant of Wilms tumour and spreads by lymphatics. It also metastasizes to lung.

124. Which one of the following is the earliest radiographic manifestation of childhood leukemia
- a. Radiolucent transverse metaphyseal bands
 - b. Diffuse demineralization of bones
 - c. Osteoblastic lesions in skull
 - d. Parenchymal pulmonary lesions on chest films

Ans 2, The findings of ALL in order of appearance are

1) Diffuse osteopenia

2) Leukemia line (choice a) and so on..

Ref Suttons TB of Radiology Page 1229.

125. Migratory thrombophlebitis is associated with the following malignancies except
- a. Lung cancer
 - b. Prostate cancer
 - c. Pancreas cancer
 - d. Gastro – intestinal cancer

Ans 2

126. A 35-year-old insulin dependent diabetes mellitus (IDDM) patient on Insulin for the past 10 years complains of gradually progressive painless loss of vision. Most likely he has
- a. Cataract
 - b. Vitreous haemorrhage
 - c. Total rhegmatogenous retinal detachment
 - d. Tractional retinal detachment not involving the macula

Ans 1

127. Which one of the following extraocular muscles is served by a contralateral brain stem subnucleus
- a. Superior rectus
 - b. Medial rectus
 - c. Inferior oblique
 - d. Inferior rectus

Ans 1

Ref Page 174 Harrison 16th ed. "Superior rectus is supplied by oculomotor nucleus of other side"

About levator muscle : Supplied by single central subnucleus.

Eponymic syndromes associated with oculomotor palsy (cliché questions of the past!)

In addition to ipsilateral oculomotor palsy these syndromes have the following features

128. 20-year-old student has a myopia of -2.0 D and a post traumatic nebular corneal opacity in her right eye. Which of the following is the best refractive surgery option for her
- Photorefractive keratectomy
 - LASIK
 - Radical keratotomy
 - Epikeratoplasty

Ans 1

129. A 56-year-old man has painful weeping rashes over the upper eyelid and forehead for the last 2 days along with ipsilateral acute punctate keratopathy. About a year back, he had chemotherapy for Non – Hodgkin's lymphoma. There is no other abnormality. Which of the following is the most likely diagnosis
- Impetigo
 - Systemic lupus Erythematosus
 - Herpes Zoster
 - Pyodema gangrenosum

Ans 3

130. An 18-year-old girl who was using spectacles for last 10 years, came with the history of photopsia and sudden loss of vision in right eye. Which one of the following clinical examinations should be performed to clinch the diagnosis
- Cycloplegic refraction
 - Indirect ophthalmoscopy
 - Schiotz tonometry
 - Gonioscopy

Ans 2, for diagnosing retinal detachment secondary to pathological myopia

131. A 55-year-old male presents with features of Obstructive Jaundice. He also reports a weight loss of seven kilograms in last two months. On CT scan, the CBD is dilated till the lower end and the main pancreatic duct is also dilated. Pancreas is normal. The most likely diagnosis is
- Choledocholithiasis
 - Carcinoma Gallbladder
 - Hilar Cholangiocarcinoma
 - Periampullary carcinoma

Ans 4

132. Hypoparathyroidism following thyroid surgery occurs within
- 24 hours
 - 2 – 5 days
 - 7 – 14 days

d. 2 – 3 weeks

Ans 2 (repeat November 2003 aiims)

133. Which of the following is generally not seen in idiopathic thrombocytopenic purpura (ITP)
- More common in females
 - Petechiae, ecchymosis and bleeding
 - Palpable splenomegaly
 - Increased megakaryocytes in bone marrow

Ans 3

Name	Features	Lesion
Nothnagel's syndrome	Contralateral cerebellar ataxia	Superior cerebellar peduncle.
Benedikt's syndrome	Contralateral chorea, tremor, athetosis	Red nucleus
Claude syndrome	Contralateral chorea, tremor, athetosis & Contralateral cerebellar ataxia	Red nucleus & Superior cerebellar peduncle.
[Has features of both above : Nothnagel syndrome & Benedicts]		
Weber syndrome	Contralateral hemiparesis	Cerebral peduncle

134. In which of the following conditions the head pipe appearance of the colon a barium enema is seen
- Amoebiasis
 - Ulcerative colitis
 - Tuberculosis of the colon
 - Crohn's involvement of the colon

Ans 2

135. During bilateral adrenalectomy, intraoperative dose of hydrocortisone should be given after
- Opening the abdomen
 - Ligation of left adrenal vein
 - Ligation of right adrenal vein
 - Excision of both adrenal glands

Ans 1

136. A 20-year-old female patient presented with a thyroid swelling. Most probably, the fine needle aspiration cytology will not diagnose
- Papillary carcinoma of thyroid
 - Medullary carcinoma of thyroid
 - Non – Hodgkin's lymphoma of thyroid
 - Follicular carcinoma of thyroid

Ans 4

137. A 40-year-old woman has undergone a cholecystectomy. The histopathology reveals that she has a 3 cm adenocarcinoma in the body of the gallbladder infiltrating upto the serosa. Which of the following further management would you advise her
- Chemotherapy

- b. Radiotherapy
- c. Radical Cholecystectomy
- d. Follow up with regular ultrasound examinations

Ans 4, Radiotherapy, chemotherapy is ineffective here. Radical cholecystectomy has not produced good results.

138. Which of the following statements is **incorrect** with regard to hepatorenal syndrome in a patient with cirrhosis
- a. The creatinine clearance is >40 ml/min
 - b. The urinary sodium is less than 10 mmol/L
 - c. The urine osmolality is lower than the plasma osmolality
 - d. There is poor response to volume expansion

Ans 1

The following criteria, as proposed by the International Ascites Club, help diagnose HRS:

Major criteria:

All major criteria are required to diagnose HRS.

- 1) Low GFR, indicated by a serum creatinine level higher than 1.5 mg/dL or **24-hour creatinine clearance lower than 40 mL/min**
- 2) Absence of shock, ongoing bacterial infection and fluid losses, and current treatment with nephrotoxic medications
- 3) **No sustained improvement in renal function** (decrease in serum creatinine to <1.5 mg/dL or increase in creatinine clearance to >40 mL/min) **after diuretic withdrawal and expansion of plasma volume** with 1.5 L of plasma expander
- 4) Proteinuria less than 500 mg/d and no ultrasonographic evidence of obstructive uropathy or intrinsic parenchymal disease

Additional criteria: Additional criteria are **not necessary for the diagnosis but provide supportive evidence.**

- 1) Urine volume less than 500 mL/d
- 2) **Urine sodium level less than 10 mEq/L**
- 3) **Urine osmolality greater than plasma osmolality**
- 4) Urine red blood cell count of less than 50 per high-power field
- 5) Serum sodium concentration greater than 130 mEq/L

This text is taken with thanks from

<http://www.emedicine.com/med/topic1001.htm#section-workup>, Emedicine.com Do read the text article there for a full description there. Many thanks to forum contributors regarding this question.

Now since the choice 1 is mentioned in major criteria as incorrect is the answer

139. A young patient presenting with massive hematemesis was found to have splenomegaly. In this case the most likely source to bleeding is
- a. Duodenal ulcer
 - b. Esophageal varices
 - c. Erosive mucosal disease
 - d. Gastric ulcer

Ans 2

140. Following resuscitation, a patient with bleeding oesophageal varices should be treated initially with
- a. Sclerotherapy
 - b. Sangstaken Blackmore tube
 - c. Propranolol
 - d. Surgery

Ans 1

141. A 62-year-old diabetic female patient presented with history of progressive right – sided weakness of one – month duration. The patient was also having speech difficulty. Fundus examination showed papilledema. Two months ago, she also had a fall in her bathroom and struck her head against a wall. The most likely clinical diagnosis is
- a. Alzheimer's disease
 - b. Left parietal glioma
 - c. Left MCA territory stroke
 - d. Left chronic subdural haematoma

Ans 4

142. Ramakali bai, a 35-year-old female presented with one year history of menstrual irregularity and galactorrhea. She also had off – and – on headache. Her examination revealed bitemporal superior quadrantanopia. Her fundus examination showed primary optic atrophy. Which of the following is the most likely diagnosis in this case
- a. Craniopharyngioma
 - b. Pituitary macroadenoma
 - c. Ophthalmic ICA aneurysm
 - d. Chiasmal glioma

Ans 2, pituitary adenoma is most common..

143. A young female patient with long history of sinusitis presented with frequent fever along with personality changes and headache of recent origin. The fundus examination revealed papilledema. The most likely diagnosis is
- a. Frontal lobe abscess
 - b. Meningitis
 - c. Encephalitis
 - d. Frontal bone osteomyelitis

Ans 1

144. Which one of the following is the treatment of choice for a 4 cm retroperitoneal lymph node mass in a patient with non seminomatous germ cell tumor of the testis
- a. Radical radiotherapy alone
 - b. High Orchidectomy + RPLND
 - c. RPLND alone
 - d. High Orchidectomy alone

Ans 3, This is a tricky question. We should never forget that the AIIMS people are always upto some mischief.

What the question says is that "patient with non seminomatous germ cell tumor". Now how do obtain this finding : by orchidectomy. So that means that high orchidectomy has already being done. So we do just RPLND.

145. A 13-year-old boy presents with acute onset right scrotal pain. The pain is not relieved on elevation of the scrotum and he has no fever or dysuria. The testis is enlarged and tender. His

AIPPG.com™ AIIMS NOV 2004 released answers, Discuss these at AIPPG.net forums!

routine urinary examination is normal. There is no history of trauma. Which of the following is the most appropriate management

- Immediate exploration
- Antibiotics
- Psychiatric evaluation
- Antibiotics and scrotal elevation

Ans 1

Phren's sign is negative, also no fever: these rules out acute epididymitis, so testicular torsion is suspected.

146. Which of the following produces the least damage to blood elements

- Disc oxygenator
- Membrane oxygenator
- Bubble oxygenator
- Screen oxygenator

Ans 2, Membrane oxygenator

Only 2 types of oxygenators are in use now: Membrane and Bubble. Surprisingly air bubbles in bubble oxygenator damage the blood more than membranes used in Membrane oxygenators. Also bubble oxygenators have the additional problem of **defoaming** the returning blood: So as to reduce air embolism. So Membrane oxygenators are preferred

Membranes used are of two types:

- Silicone elastomers
- Microporous polypropylene (ordinary plastic, these do well here!!)

147. A 25-year-old lady presents with spontaneous nipple discharge of 3-months duration. On examination this discharge is blood and from a single duct. The following statements about management of this patient are true except

- Ultrasound can be useful investigation
- Radical duct excision is the operation of choice
- Galactogram, though useful, is not essential
- Majority of blood-stained nipple discharge are due to Papillomas or other benign condition

Ans 2, for duct ectasia micrococotomy is done.

148. All of the following statements are correct about renal transplantation except

- Renal Transplantation is heterotopic
- Cyclosporine is the mainstay of immunosuppression
- In India, organ harvesting from Brain Dead patients is not permitted by Law
- Kidney after removal is flushed with cold perfusion solution

Ans 3, In India the law is such:

India's Human Organ Transplantation Act of 1994 allows a father, mother, brother, or sister to donate organs. Other live donors are screened by a state transplantation authorization committee to ascertain that they are donating organs exclusively because of emotional attachment to patients and not for monetary or material gain. Brain dead patients are allowed, why should they not be? Only thing is that is we don't have a proper

system for harvesting organs from willing patients, and in India Live transplants exceed brain dead transplants.

This is bad, considering the survival of unrelated brain dead donor is not much lower than living related donor, with the use of cyclosporine.

Kidney transplantation in Adults (most common) is heterotopic meaning at different site than normal. It is placed over psoas major below the normal location. Also left side is preferred for transplantation. And in children transplantation is at same place.

149. All of the following statements are true about repair of groin hernias except

- Lichtenstein tension free repair has a low recurrence rate
- TEPP repair is an extraperitoneal approach to laparoscopic repair of groin hernia
- In Shouldice repair, non-absorbable mesh is used
- The surgery can be done under local anaesthesia in selected cases

Ans 3, Shouldice repair mesh is not used but double breasting is done.

About 1: I have seen many trials documenting less recurrence in Lichtenstein tension free repair.

About 2: laparoscopic repair of groin hernia is of two types TEPP and TAPP

TEPP = Trans-extra peritoneal preperitoneal

TAPP = transabdominal preperitoneal (TAPP) (hernia repair)

Anesthesia is usually general but local, spinal may be used also.

150. A 25-year-old male presents to Emergency with history of road traffic accident two hours ago. The patient is hemodynamically stable. Abdomen is soft. On catheterization of the bladder, hematuria is noticed. The next step in the management should be

- Immediate laparotomy
- Retrograde Cystourethrography (RGU)
- Diagnostic Peritoneal Lavage (DPL)
- Contrast Enhanced Computed Tomography (CECT) of Abdomen

Ans 4, Since the patient is stable & Abdomen is soft: intra abdominal bleed is ruled out So no need for DPL / FAST (Focused Assessment with Sonography for Trauma.)

Now if we had suspected urethral pathology (rupture / injury secondary to pelvic fracture) we would have first done RGU (Retrograde Cystourethrography) then attempted catheterization. After catheterization RGU is not performed as it will not tell us about urethral pathology accurately.

Now coming to the answer "CECT" Contrast enhanced CT of abdomen: we will do this investigation searching for solid organ injuries. We are also looking for source of hematuria (most probably renal in this case). Also CT will help imaging the following

- Pancreas, duodenum, and genitourinary system.

- Associated injuries, notably vertebral and pelvic fractures and injuries in the thoracic cavity.
- CT has less sensitivity for diagnosing diaphragmatic, and hollow viscus injuries

So the answer is CECT

151. Which of the following is the best – known metabolic function of the lung
- Inactivation of serotonin
 - Conversion of angiotensin – I to angiotensin II
 - Inactivation of bradykinin
 - Metabolism of basic drugs by cytochrome P – 450 system

Ans 2.

Best known function: Means Conversion of angiotensin – I to angiotensin II

152. When the aviator is subjected to negative G
- The hydrostatic pressure in veins of lower limb increases
 - The cardiac output decreases
 - Black out occurs
 - The cerebral arterial pressure rises

Ans 4


153. The normal value of P50 on the oxyhaemoglobin dissociation curve in an adult is
- 1.8 kPa
 - 2.7 kPa
 - 3.6 kPa
 - 4.5 kPa

Ans 3

154. Which combination of the following statements is correct with reference to hypoxia
- When it is severe, causes stimulation of the sympathetic nervous system
 - It leads to the accumulation of hydrogen and lactate ions
 - It causes decreases in cerebral blood flow
 - If it is chronic, causes rightward shift of oxygen Hb curve
- All of the above statements are correct
 - b & c
 - a, b, & d
 - b, c & d

Ans 3, Hypoxia never causes vasoconstriction in the body (except the lungs). In fact hypoxia is a strong vasodilator itself. For example in Peripheral arterial disease: vasodilator drugs don't do much since the vessels are already dilated due to hypoxia.

155. Examine the shape of the flow volume curve carefully



This flow volume loop indicates one of the following

- Normal
- Extra thoracic obstruction
- Intra thoracic obstruction
- Fixed large airway obstruction

Ans 1, unless values are mentioned we should consider this as normal. Normal and extra thoracic will have same shape, Ref Harrison.

156. A baby girl presents with bilateral inguinal masses, thought to be hernias but are found to be testes in the inguinal canals. Which karyotype would you expect to find in the child
- 46, XX
 - 46, XY
 - 47, XXY
 - 47, XYY

Ans 2, this is testicular feminizing syndrome. Since the genitalia are those of female (normal) and testes are present. Its pathology is androgen insensitivity.

157. All of the following muscles undergo paralysis after injury to C5 and C6 spinal nerves except
- Biceps
 - Coracobrachialis
 - Brachialis
 - Brachioradialis

Ans 4, Root value of nerve supply of brachioradialis is C7,C8.

158. All of the following are characteristic of a bronchopulmonary segment, except
- It is surgically respectable
 - It is named according to the segmental bronchus supplying it
 - It is drained by intrasegmental branch of pulmonary vein
 - It is the largest subdivision of a lobe

Ans 3, (it is intersegmental!)

159. Injury to the common peroneal nerve at the lateral aspect of head of fibula result in all of the following except
- Weakness of ankle dorsi – flexion
 - Foot drop
 - Loss of ankle reflex
 - Sensory impairment of lateral aspect of leg extending to the dorsum of foot

Ans 3

AIPPG.com™ AIIMS NOV 2004 released answers, Discuss these at AIPPG.net forums!

160. The mesentery of small intestine, along its attachment to the posterior abdominal wall, crosses all of the following structures except

- Left gonadal vessels
- Third part of duodenum
- Aorta
- Right ureter

Ans 1, ref awaited.

161. Venous drainage from neurohypophysis is routed through all of the following except

- Portal vessels to adenohypophysis
- Superior hypophyseal veins to ventricular tanycytes
- Inferior hypophyseal veins to dural venous sinuses
- Capillaries to median eminence and hypothalamus

Ans 2, Rest all choices are mentioned in Grays, We have put up a little description of tanycytes for you to see.

About Tanycytes: These are highly specialized cells, that extend bleb-like protrusions and microvilli into the cerebrospinal fluid (CSF) at their ventricular surface and long cytoplasmic processes ventrally into the substance of the median eminence.

Tanycytes are presumed to have other important neuroendocrine functions that may supercede their function as barrier cells. **The close association of tanycyte foot processes with the basal lamina of the portal capillaries and with individual axon terminals** could create a retractable barrier to regulate the **diffusion of secretory products entering** or exiting specific regions of the portal capillary plexus or from axon terminals.

162. The efferent fiber bundle of the substance nigra transmits dopamine to one of the following areas

- Thalamus
- Corpus striatum
- Tegmentum of pons
- Tectum of midbrain

Ans 2

163. A posteriorly perforating ulcer in the pyloric antrum of the stomach is likely to produce initial localized peritonitis or abscess formation in the

- Greater sac
- Left subhepatic and hepatorenal spaces (pouch of Morrison)
- Omental bursa
- Right subphrenic space

Ans 3, omental bursa is another name for lesser sac!

164. Knowledge of the segmental cutaneous innervation of the skin of the lower extremity is important in determining the level of intervertebral disk disease. Thus, S1 nerve root irritation will result in pain located along the

- Anterior aspect of the thigh
- Medial aspect of the thigh
- Anteromedial aspect of the leg
- Lateral side of the foot

Ans 4.

165. A 59-year-old man complains of recurrent attacks of pain in the region of left shoulder radiating to sternum and the pit of stomach. The attacks of pain came at lengthy intervals until the last two days when it became continuous. The physician diagnosed it as angina pectoris. In this case the pain pathway from the heart is carried by

- Superior cervical cardiac nerve
- Middle and inferior cervical cardiac nerve
- Thoracic splanchnic nerve
- Vagus

Ans 3

166. Which one of the following amino acids is most likely to be found in the transmembrane region of a protein

- Lysine
- Arginine
- Leucine
- Aspartate

Ans 3

167. Which one of the following statements about Hemoglobin S (HbS) is not true

- Hemoglobin HbS differs from hemoglobin HbA by the substitution of Val for Glu in position 6 of the beta chain
- One altered peptide of Hb S migrates faster towards the cathode (-) than the corresponding peptide of HbA
- Binding of HbS to the deoxygenated HbA can extend the polymer and cause sickling of the red blood cells
- Lowering the concentration of deoxygenated Hb S can prevent sickling

Ans 2, converse is true, it moves towards anode. Ref Lippincott Biochemistry 2nd edition. (for those who haven't bought the book yet: buy the new 3rd edition with colour)

Also choice 3, is wrong as HbS + HbS leads to sickling but we feel that this is a better answer.

168. The following are true about Tumor Suppressor Gene p53 except

- It regulates certain genes involved in cell cycle regulation
- Its increased levels can induce apoptosis
- Its activity in the cells decreases following UV irradiation and stimulates cell cycle
- Mutations of the p53 gene are the most common genetic alteration seen in human cancer

Ans 2 [Dr. Swapnil Kothari]

Increased levels of P53 are not seen, rather its decreased levels cause resistance to apoptosis.

p53

Deletion Point mutation

Loss of p21 Cipl / Waf1-mediated checkpoint control > genomic instability > Resistance to apoptosis

169. During the dark phase of visual cycle, which form of vitamin A combines with opsin to make Rhodopsin

- All trans – Retinaldehyde
- All trans – Retinol
- 11 – cis – retinaldehyde

- d. 11 – cis – Retinol

Ans 3, Addition information: isotretinoin the drug used for acne is a 13 cis retinaldehyde.

170. Which one of the following microorganisms uses antigenic variation as a major means of evading host – defences
- Sterptococcus pneumoniae
 - Borrelia recurrentis
 - Mycobacterium tuberculosis
 - Listeria monocytogenes

Ans 2, Borrelia recurrentis , Fever recurs when antigenic variation occurs, and when all 4-5 possible variations have occurred then fever subsides.

About 4 : Listeria creates holes in phagolysosomes and escapes!

171. Which one of the following is not a prion associated disease
- Scrapie
 - Kuru
 - Creutzfeldt – Jakob disease
 - Alzheimer's disease

Ans 4

172. Oral rehydration mixture contains glucose and sodium because both of them
- Are needed to maintain the plasma osmolality
 - Are prominent energy sources for the body
 - Facilitate the transport of each other from the intestinal mucosa to the blood
 - Are required for the activation of sodium potassium ATPase

Ans 3

173. The following interleukin is characteristically produced a Th1 response
- IL – 2
 - IL – 4
 - IL – 5
 - IL -10

Ans 1

Th1 response = IL 1,2
Th2 response = IL 4,5

174. Which one of the following acts to increase the release of Ca²⁺ from endoplasmic reticulum
- Inositol triphosphate
 - Parathyroid hormone
 - 1, 25 – dihydroxy cholecalciferol
 - Diacglycerol

Ans 1

175. Increased susceptibility to breast cancer is likely to associated with a mutation in the following gene
- P53
 - BRCA – 1
 - Retinoblastoma (Rb)
 - H – Ras

Ans 2

Other genes associated with Breast Cancer:

- Overexpression of Cyclin E
- Amplification of Cyclin D
- Amplification of ERB-B2
- Amplification of INT-2

Also remember that Transtuzumab is a drug for **Her-Neu positive** breast cancers.

176. Which of the following techniques uses piezoelectric crystals
- Ultrasonography
 - NMR imaging
 - X- ray diffraction
 - Xeroradiography

Ans 1

177. Erythropoiesis is promoted by all of the following except
- ACTH
 - Thyroxine
 - Oestrogen
 - Prolactin

Ans 3

178. The molecular weight of a protein can be determined by
- Native Poly Acrylamide Gel Electrophoresis (PAGE)
 - Sodium Dodecyl Sulphate h-PAGE
 - Isoelectric focusing
 - Ion Exchange Chromatography

Ans 2

SDS-PAGE is widely used to estimate the molecular weights of peptides by comparison of motilities with those of standards of known molecular weight." - Harper, 25/e, Pg/43

179. Weight of an Indian reference woman is
- 45 kg
 - 50 kg
 - 55 kg
 - 60 kg

Ans 2, Indian reference man is 60 Kgs

180. Orthotolidine test is used to determine
- Nitrates in water
 - Nitrites chlorine in water
 - Free and combined chlorine in water
 - Ammonia content in water

Ans 3

181. The analytical study where population is the
- Cross sectional
 - Ecological
 - Case – control
 - Cohort

Ans 3, this is the definition of cross sectional studies.

182. An outbreak of streptococcal pharyngitis has occurred in a remote village. In order to carry out the epidemiological investigations of the outbreak it is necessary to perform the culture of the throat swab of the patients suffering from the disease. The transport media of choice would be
- Salt mannitol

- b. Pike media
- c. Stuart media
- d. Cary Blair media

Ans 2

183. Which one of the following arbovirus disease has not been reported in India

- a. Japanese Encephalitis
- b. Yellow fever
- c. Chikungunya fever
- d. Kyasanur Forest Disease

Ans 2, That is why we need a vaccination certificate. Yellow fever vaccine is effective 10 days after vaccination and remains so till 35 years!

184. As compared to a routine case control study, nested case control study avoids problems (in study design) related to

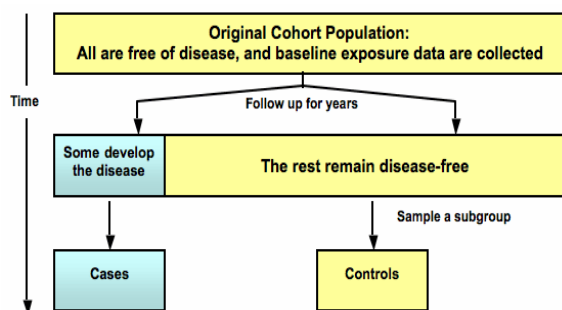
- a. Temporal association
- b. Confounding bias
- c. Need for long follow up
- d. Randomization

Ans 1, see this text below

[I am not sure about answer being 2 also? But 1 is a better answer]

What is a nested case control study?

A nested case-control study is a type of case-control study that draws its cases and controls from a cohort population **that has been followed for a period of time.**



Advantages : Nested studies

- 1) Can utilize the exposure and confounder data originally collected before the onset of the disease, **thus reducing potential recall bias and temporal ambiguity**
- 2) Include cases and controls drawn from the same cohort, **decreasing the likelihood of selection bias.**

Also let me tell a related question commonly marked wrongly:

Q: At launch of study program, many respondents were invited, some of whom fail to come. It's called as

- 1. response bias
- 2. Volunteer bias
- 3. berkesonian bias
- 4. selection bias

Ans 2, Volunteer Bias

>Response bias (most popularly quoted answer but false):

What is it?

It is the inclination of respondents in a research survey to give the answer that they believe the interviewer wants to hear. So it is not the case here.

About the answer to this question:

> **Volunteer bias:** people who sign up or come for studies are well known to be much healthier than the general population.

185. To test the association between risk factor and disease, which of the following is the **weakest** study design

- a. Case – control study
- b. Ecological study
- c. Cohort Study
- d. Cross – sectional study

Ans 2

The six study designs in the Hierarchy of evidence

1. Case series--what clinicians see
2. Ecological--geographical comparisons
3. Cross sectional--survey, a snapshot in time
4. Case-control--compare people with and without a disease
5. Cohort--follow people over time to see who gets the disease
6. Randomised controlled trial (RCT) --the human experiment

This ranking is sometimes referred to as the hierarchy of evidence, with stronger evidence coming from the studies later rather than earlier on in the list.

So the answer is ecological study

[Courtsey Dr Suganya, Via Forum, Chennai]

186. All of the following statements regarding Dracunculiasis are true except

- a. India has eradicated this disease
- b. Niridazole prevents transmission of the disease
- c. The disease is limited to tropical and subtropical regions
- d. No animal reservoir has been proved

Ans 2. It doesn't prevent transmission. Only the sanitation of wells can prevent transmission which is achieved.

187. In which of the Indian states the maximum number of AIDS cases have been reported till now

- a. Delhi
- b. Kerala
- c. Tamil Nadu
- d. Bihar

Ans 3, Three states with maximum HIV rates are ASSAM, MAHARASHTRA, TAMIL NADU. Here the goal of NACO is to reduce the prevalence to 5 % by 2007.

188. Which one of the following statements is false regarding vincristine

- a. It is an alkaloid
- b. Its use is associated with neurotoxicity
- c. It does not cause alopecia

AIPPG.com™ AIIMS NOV 2004 released answers, Discuss these at AIPPG.net forums!

- d. It is useful drug for induction of remission in acute lymphoblastic leukaemia

Ans 3

189. All of the following statements about mosquito are true except
- It is a definitive host in malaria
 - It is a definitive host in filaria
 - Its life cycle is completed in 3 weeks
 - The female can travel upto 3 kilometers

Ans 2, For Filaria sexual cycle is in MAN so MAN is the definitive host.

190. All of the following statements about quarantine are true except
- It is synonymous with isolation
 - Absolute quarantine is restriction during the incubation period
 - Exclusion of children from schools is an example of **modified** quarantine
 - Quarantine should not be longer than the longest incubation period

Ans 1

191. A total 5000 patients of glaucoma are identified and surveyed by patient interviews regarding family history of glaucoma. Such a study design is called
- Case series report
 - Case – control study
 - Clinical trial
 - Cohort study

Ans 1, Don't get confused by the number of patients

192. In a 3 X 4 contingency table, the number of degrees of freedom equals to
- 1
 - 5
 - 6
 - 12

Ans 3, (n-1) (n-1)

193. The literacy rate of Indian Population as per Census 2001 is
- 54.5%
 - 65.4%
 - 85.8%
 - 75.5%

Ans 2

Literacy rates India: 2001

Male : 76 %

Female" 54 %

Total (average of above 2) : 65.38 %

Highest in kerela = 90 % and lowest in Bihar (obviously with likes of Laloo and Rabri ..(Sic) = 47.53 %

194. In assessing the association between maternal nutritional status and the birth weight of the newborns, two investigators A and B studied separately and found significant results with p values 0.02 and 0.04 respectively. From this information, what can you infer about the magnitudes of association found by the two investigators
- The magnitude of association found by Investigator A is more than that found by B

- The magnitude of association found by Investigator B is more than that found by A
- The estimates of association obtained by A and B will be equal, since both are significant
- Nothing can be concluded as the information given is inadequate

Ans 1, P value is considered a measure of significance of study. There is a double difference in P value here. Also lesser the P value more significant the association. P values are routinely used to compare studies in meta analysis. (Agreed bit are significant but association is NOT same: option 3)

195. A Cardiologist wants to study the effect of an anti – hypertensive drug. He notes down the initial systolic blood pressure (mmHg) of 50 patients and then administers the drug on them. After a week's treatment, he measures the systolic blood pressure again. Which of the following is the most appropriate statistical test of significance to test the statistical significance of the change in blood pressure
- Paired ttest
 - Unpaired or independent t – test
 - Analysis of Variance
 - Chi – square test

Ans 1, before and after for a same sample = paired T test

196. The number of malaria cases reported during the last 10 years in a town are given below; 250,320,190,300,5000,100,260,350,320& 160. The epidemiologist wants to find out the average number of malaria cases reported in that town during the last 10 years. The most appropriate measures of average for this data will be
- Arithmetic mean
 - Mode
 - Median
 - Geometric mean

Ans 3, The question asks most appropriate, this means a measure which would be most representative. A single value of 5000 should be considered an aberration and ignored. So median will be most appropriate. MODE is also incorrect.

197. In a group of patients presenting to a hospital emergency with abdominal pain, 30% of patients have acute appendicitis, 70% of patients with appendicitis have a temperature greater than 37.5°C and 40% of patients without appendicitis have a temperature greater than 37.5°C. Considering these findings, which of the following statements is correct
- The sensitivity of temperature greater than 37.50C as a marker for appendicitis is 21/49
 - The specificity of temperature greater than 37.50C as a marker for appendicitis is 42/70
 - The positive predictive value of temperature greater than 37.50C as marker for appendicitis is 21/30
 - The specificity of the test will depend upon the prevalence of appendicitis in the population to which it is applied

Ans 2, The PPV depends upon prevalence so PPV can never be found out by percentages. A common error was to assume a 100 sized sample: Then PPV option appeared correct. Calculations will follow later.

AIPPG.com™ AIIMS NOV 2004 released answers, Discuss these at AIPPG.net forums!

198. A patient with leprosy had slightly erythematous, anaesthetic plaques on the trunk and upper limbs. He was treated with paucibacillary multidrug therapy (PB – MDT) for 6 months. At the end of 6 months, he had persistent erythema and induration in the plaque. The next step of action recommended by the World Health Organization (WHO) in such a patient is
- Stop antileprosy treatment
 - Continue PB – MDT till erythema subsides
 - Biopsy the lesion to document activity
 - Continue dapsone alone for another 6 months

Ans 3 , read below.

Criteria for relapse in WHO multibacillary regimen

Among the criteria for relapse are the following (16):

- new skin lesions;
- new activity in previously existing skin lesions;
- bacteriological index (BI) 2+ or more in two sets of skin smears;
- new loss of nerve function;
- histological evidence of relapse in skin or nerve biopsy;
- lepromatous activity in the eye(s).

Criteria for relapse in Paucibacillary regimen

The following seven criteria were proposed for defining relapse in PB leprosy

(ref Pandian TD et al. A study of relapse in non-lepromatous and intermediate groups of leprosy. *Indian Journal of Leprosy*, 1985, 57:149–158 and WHO)

- extension of the lesion
- infiltration
- erythema
- occurrence of fresh lesions
- pain and tenderness of nerve
- new paralysis of muscles
- bacteriological positivity.

This is how WHO summarises this information

“Relapse, in MB leprosy, is defined as the multiplication of *M. leprae*, suspected by the marked increase (at least 2+ over the previous value) in the BI at any single site, usually with evidence of clinical deterioration (new skin patches or nodules and/or new nerve damage). This can be confirmed in most cases by the growth of *M. leprae* in the mouse footpad system. Recognition of relapse in paucibacillary leprosy is somewhat difficult as it is hard to distinguish it from reversal reaction. In theory, a therapeutic test with corticosteroids may be able to distinguish between these two phenomena: definite improvement within four weeks of corticosteroid therapy denoting reversal reaction, and non-response to corticosteroids during the same period favouring the diagnosis of clinical relapse.”

So it may be said that the question is asking about a persistent / relapse case of paucibacillary leprosy.

Now WHO says two things about relapse : 1) in case of relapse search for other causes as it is very rare (HIV / immuosupression etc)

2) How to manage relapse?

Read this to find out

“If reliable facilities for skin smears are available, then ideally all patients should have one examination at the start of treatment. This is to prevent an MB case being treated as PB. With fixed-duration treatment regimens, skin smears are not needed either to stop treatment or as a routine measure for follow-up of patients after completion of treatment. **In patients where clinical deterioration/relapse is suspected, skin smears should be taken from the most active sites.** In view of the increasing prevalence of human immunodeficiency viruses (HIV) and hepatitis B infections in many countries where leprosy remains endemic, the number of skin-smear sites and the frequency of smear collection should be limited to a minimum. Remember that all skin-piercing procedures have the potential risk of transmitting HIV and hepatitis infections.”

All data is taken from WHO documentation , from which any answer should be based. Remember that WHO has now released guidelines for follow up also. Also relapse rate by MDT therapy (for TT or LL / any) is just 1 / 1000 human years, justifying the use of multidrug therapy.

Also note that INDIA represents 76 % of global burden of leprosy and for the first time in 2003, targets were not set for case detection, this is good as previously health workers falsely reported cases of leprosy to meet targets leading to wastage of medicines supplied by WHO. All medicines of MDT are supplied free by WHO and shipped to 4-5 distribution centres in India.

199. A 40-year-old woman presented with a 8 month history of erythema and swelling of the periobital region and papules and plaques on the dorsolateral aspect of forearms and knuckles with ragged cuticles. There was no muscle weakness. The most likely diagnosis is

- Systemic lupus erythematosus
- Dermatomyositis
- Systemic sclerosis
- Mixed connective tissue disorder

Ans 2, this is a variant of Dermatomyositis (sine myositis).

It is dermatomyositis as

a) A variant of dermatomyositis (sine myositis) presents with no weakness, also SLE like rash is often found in dermatomyositis. Not only the sites of involvement (periobital and knuckles) is classical for dermatomyositis, but also note that ragged cuticles is also specific for dermatomyositis.

b) MCTD presents with GI symptoms in 70 %, raynauds, arthralgias, myalgias most commonly.

c) SLE diagnosis required 4 out of 11 criteria which are not present here.

200. A 40-year-old male had multiple blisters over the trunk and extremities. Direct immunofluorescence studies showed linear IgG along the basement membrane. Which of the following is the most likely diagnosis

- a. Pemphigus vulgaris
- b. Pemphigus foliaceus
- c. Bullous Pemphigoid
- d. Dermatitis herpetiformis

Ans 3, Basement membrane deposits are found in Bullous Pemphigoid.

AIPPG is a no profit educational resource devoted to the field of medical post graduation entrance.

If you are an author and wish that AIPPG publishes your book email **books[at] aippg. Info**

Contact us using the feedback form [form here](#)
<http://www.aippg.net/forum/viewforum.php?f=9>