

1. When the axial length of the eyeball is changed by 1 mm then the power changes by
  - a. 2 dioptres
  - b. 3 dioptres
  - c. 4 dioptres
  - d. 1 dioptres
  
2. A patient presented with a red eye with complaints of pain, photophobia, and blurring after trauma to his eye with a vegetable matter. On examination the cornea there was a dendritic ulcer. The corneal scrapings were taken and examined, microscopy showed macrophage like cells. The corneal scrapings were cultured over chocolate agar and blood agar but there was no growth. But on culturing over 5% non-nutrient agar with an overlay of E.coli there were plaque formations. The likely etiological agent is
  - a. Acanthameaba
  - b. Herpes simplex
  - c. Adeno virus
  - d. Candida
  
3. Horner's syndrome is best explained as having
  - a. Miosis and Exophthalmos
  - b. Miosis and ptosis
  - c. Mydriasis and enophthalmos
  - d. Miosis and ptosis
  
4. In a lesion in the optic radiation involving the Meyers loop causes which of the following
  - a. Homonymous hemianopia
  - b. Superior quadrantonopia
  - c. Central scotoma
  - d. Bilateral hemianopia
  
5. In a lesion in which of the following would lead to internuclear ophthalmoplegia
  - a. Lateral lemniscus
  - b. Medial longitudinal fasciculus
  - c. Parapontine reticular fibres
  - d. Occipital lobes
  
6. In a patient with multiple bilateral nasal polyps with x ray showing opacity in the Para nasal sinuses .The treatment consists of all of the following except
  - a. Antihistamines
  - b. Corticosteroids
  - c. Amphoterecin B
  - d. Epinephrine
  
7. An 18-year-old boy presented with repeated epistaxis and there was a mass arising from the lateral wall of his nose extending into the nasopharynx. It was decided to operate him. All of the following are true regarding his management except
  - a. Requires adequate amount of blood to be transfused
  - b. A lateral rhinotomy approach may be used
  - c. Transpalatal approach used
  - d. Trans maxillary approach
  
8. Which is the best rinsing solution that can be used in the extra capsular cataract extraction

- a. Ringer lactate
  - b. Normal saline
  - c. Balanced salt solution
  - d. Balanced salt solution with glutathione
9. The oldest cells in a lens are present in
- a. Anterior capsule
  - b. Posterior capsule
  - c. Nucleocortical junction
  - d. Nucleus
10. A patient presented with a 15 days history of proptosis in his right eye .His vision was found to be 6/12 in that eye, and he complained of pain on eye movement. There was difficulty in upward and downward gaze movements. Ultrasound and CT scans showed a cystic lesion with hyperdense opacity within it, located in the superior oblique muscle. The diagnosis is
- a. Cysticercosis cellulosae
  - b. Orbital abscess
  - c. Hemangioma
  - d. Dermoid
11. Recurrent chalazion is predisposed to develop
- a. Basal cell carcinoma
  - b. Adenocarcinoma
  - c. Squamous cell carcinoma
  - d. Epidermoid carcinoma
12. In a patient hoarseness of voice was found to be having pachydermis larynges .All of the following are true except
- a. It is a hyperkeratotic lesion present within the anterior 2/3rd of the vocal cords
  - b. It is not premalignant
  - c. Diagnosed is made by biopsy
  - d. On microscopy it shows acanthosis and hyperkeratosis
13. In a patient presenting with well defined rash with scales over the elbows and the knees. Which of the following simple bedside test would help in coming to a diagnosis
- a. Tzank smear
  - b. Auspitz sign
  - c. Split skin smear
  - d. Examination under KoH solution.
14. Treatment of pustular psoriasis is
- a. Hydroxyurea
  - b. Retinoids
  - c. Thalidomide
  - d. Steroids
15. In a patient presenting with nodulocystic lesions the treatment would include
- a. Retinoids
  - b. Antibiotics
  - c. Steroids

[contribute questions /choices /answers or explanations by using this form \(click here a new window will open\)](#)

16. A woman presented with an itchy lesion below her right breast. On examination it was found to have well formed ring scales. The diagnosis is
  - a. Candida
  - b. Trichophyton rubrum
  - c. Lichen planus
  - d. Bacterial infection
  
17. Flourescein angiography is used to identify lesions in all of the following except
  - a. Retina
  - b. Iris
  - c. Lens
  - d. Optic nerve head
  
18. In a patient presenting with hemoptysis the x-ray was found to be normal. The investigation done to aid in diagnosis is.
  - a. Helical CT scan
  - b. High resolutions CT scan
  - c. Bronchoscopy
  - d. MRI
  
19. A patient suffering from HIV came with history of difficulty in breathing. The X ray showed the parahilar region to be widened. But there was no adenopathy or effusion. The likely cause of his problem is
  - a. Pneumocystis carinii pneumonia
  - b. Kaposi's sarcoma
  - c. Tuberculosis
  - d. CMV
  
20. In a patient with mitral stenosis will show all of the following findings on x-ray except
  - a. Raising up of the left bronchus
  - b. Shadow in shadow appearance
  - c. Kink in the esophagus in barium swallow studies
  - d. Obliteration of retrosternal shadow on lateral x ray
  
21. In a patient with air embolism all of the following are true except
  - a. TEE (transesophageal echo) is the most sensitive investigation
  - b. It should be measured over a continous cycle
  - c. It can calculate the volume of the air
  - d. It interferes with Doppler readings when they are used together
  
22. A 60-year man gives a 10-year history that he suspects his neighbours and he feels that whenever he passes by they sneeze and plan against behind his back. He feels that his wife has been replaced by a double and calls police for help. He is quite well groomed, alert, occasionally consumes alcohol. The likely diagnosis is
  - a. Paranoid personality
  - b. Paranoid schizophrenia
  - c. Alcoholic hallucinations
  - d. Dementia

23. A 66-year-old lady is brought in by her 6 children saying that she has gone senile. Six months after her husband's death she has become more religious, spiritual and gives a lot of money in donation. She is occupied in too many activities and sleeps less. She now believes that she has a goal to change the society. She does not like being brought to the hospital and is argumentative on being questioned on her doings. The diagnosis is
- Manic excitement
  - Brief reaction
  - Dementia
  - Depression
24. A teacher complains that a 9-year-old child does not pay attention in the class, gets distracted very fast and also disturbs and distracts the other students. The diagnosis is
- Autism
  - Attention deficit hyperkinetic disease
  - Conduct disorder
25. A patient is brought with a 6 months history of odd behaviour. There is a history of a family member having disappeared some years back. He seems to be talking to himself and sometimes muttering to himself loudly. The diagnosis is
- Depression
  - Schizophrenia
  - Paranoia
  - Mania
26. Regarding Temporomandibular joint least vascularity is seen in which of the following
- Anterior portion
  - Central part
  - Posterior part
  - Articular cartilage
27. Protonopia implies complete abnormality in which of the following colours
- Red
  - Blue
  - Green
  - Yellow
28. When chorionic villous biopsy is done before ten weeks it causes which of the following adverse effects
- Fetomaternal haemorrhage
  - Cardiac defects
  - Limb defects
  - Renal defects
29. In a patient with red degeneration all of the following are true except
- It occurs as it outgrows its blood supply
  - It presents with pain abdomen and nausea
  - Surgery is required in treatment
  - It occurs only during pregnancy

30. The complement is fixed best by which of the following immunoglobulins
- IgG
  - IgM
  - IgA
  - IgD
31. Regarding the HMG CoA reductase inhibitors all of the following are true except
- The CNS accumulation of drugs Simvastatin and Lovastatin is high and it is less for Pravastatin and Fluvastatin
  - Simvastatin is extensively metabolised and Pravastatin is least
  - Bioavailability is minimally modified when Pravastatin is taken along with food
  - Fibrinogen levels are increased by Pravastatin
32. All of the following have proximal myopathy except
- Myotonic dystrophy
  - Spinomuscular atrophy
  - Polymyositis
  - Duchenne muscular dystrophy
33. Skeletal maturation depends most upon
- Growth hormone
  - Thyroxin
  - Testosterone and estrogen ratio
  - Cortisol
34. Toxoplasmosis in the foetus can be best confirmed by
- IgG antibodies against Toxoplasma in the mother
  - IgM antibodies against toxoplasma in the Foetus
  - IgG antibodies against toxoplasma in the mother
  - IgG antibodies against toxoplasma in the foetus
35. Which of the following branches of External carotid artery is arising from the medial side
- Superior Thyroid
  - Ascending pharyngeal
  - Internal maxillary
  - Superior Lingual
36. In a patient with medial condyle fracture with injury to a nerve passing by leads to all of the following except
- Weakness of adduction of fingers
  - Ulnar deviation and wrist flexion affected
  - Total paralysis of 4th and 5th fingers
  - Sensory loss over (...)
37. A patient Rameshwar presented with weakness of hand over a past few months with atrophy of the thenar eminence on examination. Which of the following nerves is implicated

- a. Ulnar
  - b. Median
  - c. Radial
  - d. Axillary
38. Mental foramen is closely related to which of the following
- a. 2nd premolar
  - b. 1st molar
  - c. 1st molar maxillary
  - d. Canines of mandible
39. To give inferior alveolar nerve block the nerve is approached medial to pterygomandibular raphe between the buccinator and
- a. Temporalis
  - b. Internal pterigoid
  - c. Superior pharyngeal constrictor
  - d. Middle pharyngeal constrictor
40. Blood supply to the first two cms of duodenum is from all of the following except
- a. Supradoudenal
  - b. Gastrodoudenal
  - c. Hepatic
  - d. Superior pancreaticodoudenal
41. All of the following are tributaries anatomising with cavernous sinus except
- a. Superficial middle cerebral vein
  - b. Superior petrosal
  - c. Inferior ophthalmic
  - d. Sphenoparietal veins
42. In a mutation if valine is replaced by which of the following would not result in any change in the amino acid
- a. Proline
  - b. Glycine
  - c. Aspartic acid
  - d. Leucine
43. A mutation in the codon, which causes a change in the amino acid being coded, is referred to as
- a. Missense mutation
  - b. Recombination
  - c. Somatic mutation
  - d. Mitogenesis
44. In a patient with starvation for 72 hours which of the following would be seen
- a. Increased ketosis due to breakdown of fats
  - b. Increased gluconeogenesis by muscle protein breakdown
  - c. Increased Glycogenolysis
  - d. Increased glycosis
45. Which of the following membranes would be having highest protein content

- a. Inner mitochondrial membrane
  - b. Outer mitochondrial membrane
  - c. Plasma membrane
  - d. Myelin sheath
46. The presence of lone pair on the oxygen in water molecule results in
- a. Makes water apolar solvent
  - b. Slightly positive charge
  - c. Slightly negative charge
  - d. Covalent bond in ice
47. Defect in folding proteins would result in a clinical disease in which of the following
- a. Myopia
  - b. Hypothyroidism
  - c. Migraine
  - d. Kuru
48. When deoxyhemoglobin gets converted into oxyhemoglobin the changes seen would include
- a. Haemoglobin becomes more acidic by accepting protons
  - b. Increased binding of 2,3 DPG
  - c. Increased binding to glutathione
  - d. Increased formation of formation of Carbamino compounds
49. In alkaptonuria there is increased pigmentation in all of the following except
- a. Eyes
  - b. Nose
  - c. Ear
  - d. Articular cartilage
50. The transfer of iron from sertoli cells to adluminal germ cells is by which of the following
- a. Transferrin
  - b. FSH
  - c. Androgen binding protein
  - d. Sulfated glycoprotein
51. All of the following cross cell membrane easily except
- a. Glucose
  - b. Glucose 6 phosphate
  - c. Nitric oxide
  - d. Carbon monoxide
52. Viscosity in synovial fluid depends upon
- a. Chondroitin sulphate
  - b. Hyaluronic acid
  - c. Keratin sulphate
53. All of the following are extracellular proteins except
- a. Laminin
  - b. Integrin
  - c. Collagen

d. Elastin

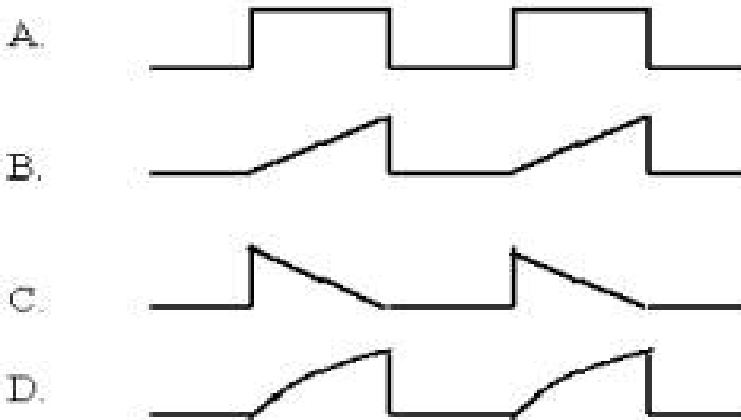
54. Anomeric c-atom is seen in which of the following

- a. Glycine
- b. Alanine
- c. Valine
- d. Leucine

55. Homeostatic mechanisms in a body system depends upon all of the following except

- a. Value of controlled variable is compared to the reference value
- b. Value of controlled variable oscillates near a set point
- c. Positive feedback stabilizes system
- d. Values revolve around the mean

56. Which of the following stimulus (equal strength) is least likely to cause a nerve stimulation [action potential].



[2 choices by dinesh p , Banglore]

57. On ascending to a height of 6500 Mts (347 mm Hg). What is the PO<sub>2</sub> of inspired moist air

- a. 53
- b. 63
- c. 73
- d. 83

58. In a study, dye ABC is used to measure cardiac output and blood volume. The dye is replaced with a new dye XYZ. A rival pharmaceutical company informs that the dye XYZ diffuses more rapidly out of the capillaries. This would affect the study by

- a. Normal cardiac output, altered blood volume estimation
- b. Altered cardiac output and blood volume
- c. Normal cardiac output and blood volume
- d. Altered cardiac output and normal blood volume

59. A substance is present in concentration of 2mg in the afferent arteries and the veins contain 0 mgs and excreted with a concentration of 2mgs in urine. True about the substance is

- a. It is freely filtered in GFR
- b. Secreted in cortical nephron
- c. Impermeable in loop of henle



- d. Absorbed in PCT
60. In a chronic smoker with mild hemoptysis He also gave a history of hypertension and obesity. Lab data showed raised ACTH levels, which were not suppressed by dexamethazone. The cause for the Cushings syndrome in the patient is
- Pituitary adenoma
  - Ectopic ACTH
  -
61. In a patient with BPH all of the following are used except
- Flutamide
  - Finasteride
  - Testosterone
  - DES
62. Acute lung injury includes all of the following except
- Aspiration
  - Toxic gas inhalation
  - Cardiopulmonary bypass with heart lung machine
  - Lung contusion
63. All of the following are seen in a patient with cystic fibrosis except
- Metabolic acidosis
  - Steatorrhoea
  - Hypochloremia
  - Reccurent pneumonias
64. Which of the following is most commonly associated with uvietis
- Still 's disease
  - Pauciarticular juvenile rheumatoid arthritis
  - Polyarticular juvenile rheumatoid arthritis
  - Rheumatoid arthritis
65. A lady with 2 children presented with a history of ammenorrhea and galactorrhea over the past 12 months. The likely diagnosis is
- Pregnancy
  - Pituitary tumour
  - Sheehans syndrome
  - Hypothyroidism
66. The most common cause of Addison disease is
- Tuberculosis
  - Autoimmune adrenelitis
  - Meningococcal septicaemia
  - Malignancy

[Discuss PG entrance questions at our "Question Forum"](#)

[Visit our message board for any query on pre pg examination](#)

67. In an accident there was rupture of the pituitary stalk. This would lead to all of the following except
- Hyperprolactinemia
  - Diabetes Insipidus
  - Hypothyroidism
  - Diabetes Mellitus
68. In a patient with NIDDM which of the following is seen
- Ketosis commonly occurs on stopping treatment
  - There are increased levels of insulin in blood
  - Pancreatic beta cells stop producing insulin
  - Hypercholesterolemia never occurs
69. Necrotizing papillitis is seen in all of the following except
- Salicylate poisoning
  - Renal vascular thrombosis
  - PNH
  - Diabetes Mellitus
70. A chronic alcoholic presented to the casualty with altered sensorium. His blood sugar level was normal. Which of the following is the treatment to be given
- IV dextrose 5%
  - IV dextrose 50%
  - Inj Vitamin B1
  - IV Normal saline
71. In the treatment of syphilis which of the following is the best mode of follow up to ensure that the patient is responding to treatment
- FTA-Abs
  - TPHA
  -
73. To say twin discordance the difference in the two twins should be
- 25% with the larger twin as index
  - 15% with the smaller twin as index
  - 25% with the smaller twin as index
  - 15% with the larger twin as index
74. If the mother is infected with hepatitis B virus and is HbsAG positive at 32 weeks of pregnancy. To prevent neonatal infection which of the following needs to be given to the newborn
- Hepatitis B vaccine
  - Human immunoglobulins
  - Hepatitis B vaccine + Immunoglobulins
  - Immunoglobulins followed by vaccine 1 month later if HbsAG negative
75. A full term baby exclusively breast fed, at the end of 1 week was passing golden yellow soft stools, and was found to be having adequate hydration and with no abnormality on systemic examination. The weight of the

neonate at the end of 1 week is just the same as it was at birth, the paediatrician should now advise

- a. Start top feeds
- b. Oral solutions along with breast-feeding
- c. Investigate for late lactic acidosis
- d. Reassure the mother that there is nothing abnormal

76. A 2-year child with Vitamin D resistant rickets was found to have the following lab data on investigation. Ca<sup>2+</sup> 9mgs/dl, phosphate 2.4 mgs/dl, alkaline phosphate 1041 IU and immunocytochemical studies showed parathormone to be 59 units. The probable diagnosis is

- a. Hypophosphatemic rickets
- b. Vitamin D dependant rickets
- c. Hyperparathyroidism
- d. Distal renal tubular acidosis

77. Skeletal maturation depends most upon

- a. Thyroxin
- b. Growth hormone
- c. Testosterone/Estrogen ratio
- d. Cortisone

78. All of the following are ductus dependent congenital heart diseases except

- a. Transposition of great vessels with intact septum
- b. Truncus arteriosus
- c. Obliterated aortic arch syndrome
- d. Hypoplastic left ventricle

79. Transient tachypnea of new born (TTN) is commonly seen in which of the following situations

- a. Full term requiring caesarian section
- b. Term requiring forceps
- c. Term requiring ventouse
- d. Premature with vaginal delivery

80. In retrolental fibroplasias the most important association has been with

- a. Intrauterine infection
- b. Low birth weight
- c. Meconium aspiration
- d. Prolonged labour

81. If the mother has been exposed to Diethylstilbestrol during pregnancy. All of the following features may be seen the child after birth except

- a. Vaginal adenosis
- b. Malformation of the vagina and uterus
- c. Microglandular hyperplasia
- d. Clear cell carcinoma

82. In which of the following sterilization procedures is best reversible

- a. Pomeroy's technique
- b. Irwinne's technique

- c. Laproscopic placement of sialatic bands
  - d. Laproscopic placement of Hulka clips
83. A neonate with severe anaemia and hepatosplenomegaly died after birth. Which of the following is the cause for his anaemia
- a. Alpha thallessima
  - b. Beta thallemia
  - c. Hereditary spherocytosis
  - d. Sickle cell anaemia
84. Which of the following is responsible for maintaining the structure of the RBC membrane
- a. Spectrin
  - b. Fibrin
  - c. Integrin
85. Pap smear would be useful in all of the following conditions except
- a. Gonococcal infection
  - b. Human papilloma virus
  - c. Trychomoniasis
  - d. Inflammatory changes
86. On examination of cervix after staining with acetic acid would help to identify all the following showing stain except
- a. Squamous metaplasia
  - b. Carcinoma in situ
  - c. Cervical dysplasia
  - d. Cervical polyp

**AIIMS MD/MS ENTRANCE EXAMINATION QUESTION**

**PAPER 12th May 2002 @aippg.com**

[Visit our AIIMS section \(click here\)](#)

87. On performing per vaginal examination the fingers could feel the anterior fontanelle and the superior orbital ridges. The presentation is
- a. Vertex
  - b. Brow
  - c. Deflexed
  - d. Extended
88. In excitation contraction coupling in smooth muscle true is
- a. The presence of intracellular calcium is essential to cause contraction
  - b. Presence of troponin is essential
  - c. Phosphorylation of actin occurs
  - d. Increased calcium in sarcoplasmic reticulum causes sustained contraction
89. All of the following are present in mucosa of small intestine except
- a. Paneth cells
  - b. Goblet cells
  - c. Neck mucosa cells

d. Stem cells

90. In study to measure BP 2 students Sameer and Rahul are conducting a study on a dog. Sameer measure BP using a mercury sphygmanometer on the right femoral artery and Rahul measures using a pressure transducer and pulse tracing on the left femoral artery. Both get a value of 100 mm Hg. After giving Inj of 30micrograms of epinephrine they measure the BP again. Sameer obtains a value of 130 mm Hg and rahul 120 mm Hg. Discrepancy in values is explained by
- Right femoral artery is more sensitive to epinephrine
  - Falsely high values at low pressures in pulse tracings
  - Falsely low values at high pressures in pulse tracings
  - Diastole period is affected by the ventricular filling
91. In a patient CVP and Intra arterial pressure were monitored. During the monitoring the patient suddenly developed an attack of supra ventricular Tachycardia. Changes seen in the pressure readings due to the effect of Tachycardia are
- Increased CVP and decreased BP
  - Increased CVP and BP
  - Decreased CVP and increased BP
  - Decreased CVP and BP
92. A cardiologist asks for measurement of electromechanical systole QS2 and left ventricular ejection time LVET, and pre-ejection period. The technician doing the study informs the cardiologist that the carotid transducer measuring pressure is not functioning. Which of the following cannot be measured
- QS2
  - LVET and PEP
  - QS2 and LVET
  - QS2 and PEP
93. Which of the following is involved is in metastasis cascade of
- Fibronectin
  - E-Cadherin
  - Type IV collagenase
  - Tyrosine kinase
94. Gastrointestinal stromal malignancy arises from which of the following
- Smooth muscle
  - Interstitial cells
  - Nerve cells of cajal
  - Vascular Endothelium
95. In tumour lysis syndrome all of the following are seen except
- Hyperkalemia
  - Hypercalcemia
  - Hyperphosphatemia
  - Hypernatremia

96. Which of the following is true regarding vascularity of lung
- Hypoxia causes vasodilatation
  - Distended capillaries in lower lobe
  - Increased perfusion of apical lobe
  - Pulmonary resistance is half of the systemic vascular resistance
97. Foreign body aspiration in supine position causes which of the following parts of the commonly to be affected
- Apical lobe of right lung
  - Posterobasal segment of Left lung
  - Apical part of right lower lobe
  - Apical left lobe
98. Regarding hydatid cyst of lung which of the following is true
- Always associated with cyst in the liver
  - Calcification is common
  - More common in lower lobe
  - Never ruptures
99. Myopathy is caused by all of the following except
- Oral Prednisolone
  - IV hydrocortisone
  - Chloroquine
  - Chloramphenicol
100. Pancreatitis is caused by all of the following except
- Methyl Dopa
  - Corticosteroid
  - Furosemide
  - Somatostatin
101. Gingival hyperplasia, hirsutism, osteomalacia is caused by which of the following drugs
- Carbamazepine
  - Sodium Valproate
  - Phenytoin
  - Furosemide
102. Enantiomeric drugs are used in racemic mixtures, which have different pharmacokinetic and pharmacodynamic properties and also vary in the stereoisomeric responses to the receptors. Which of the following drugs is a racemic mixture
- Verapamil
  - Dilantin
  - Lithium
  - Digoxin

[contribute questions /choices /answers or explanations by using this form \(click here a new window will open\)](#)

103. All are used in acute asthma except
- Ipratropium
  - Salbutamol
  - Montelukast
  - Hydrocortizone
104. Chlorodiazepoxide used in elderly patients is more likely to cause toxicity due to all of the following reasons except
- Increased receptor sensitivity
  - Decreased plasma clearance
  - Decreased volume of distribution
  - Decreased metabolism
105. All of the following are true about beta blockers except
- Atenolol has a longer half life than Metoprolol
  - Propranolol potentiates hypoglycemia in diabetics
  - Labetalol is a non selective Beta blocker
  - Carvedilol is selective Beta-1 blocker and also has vasoconstrictor activity due to alpha 1 adrenergic blocking action
106. All of the following are true about Metformin except
- Alcohol potentiates increased lactic acidosis along with it
  - It does not cause release of insulin
  - It inhibits Glycogenolysis and increases peripheral utilization of glucose
  - Causes severe hypoglycaemia both in diabetics and non diabetics
107. All of the following drugs precipitate hypertensive crisis in pheochromocytoma except
- Propranolol
  - Saralasin
  - Phenoxybenzamine
108. Which of the following actions are associated with action on  $\mu$  receptors
- Miosis
  - Hypothermia
  - Bradycardia
  - Diuresis
109. Which of the following can be used safely in a carcinoma patient with intractable pain
- Inj Pethidine
  - Oral morphine
  - Inj ibuprofen
  - Inj Ketamine
110. Which of the following is specifically avoided in a patient with head trauma
- Diazepam
  - Morphine

- c. Phenobarbitone
  - d. Inj Ketamine
111. Antigen presenting cells are all of the following except
- a. Astrocytes
  - b. Endothelial cells
  - c. Epithelial cells
  - d. Langerhans cells
112. Child presented with fever for 2 days, altered sensorium and purpuric rash. BP was 90/60 mm Hg. Which of the following is indicated in the treatment
- a. I/V artesunate
  - b. I/V Quinine
  - c. I/V Penicillin
  - d. Chloroquine
113. A child was suffering through nephritic syndrome and had hypoalbuminemia, All the following drugs half life is altered due to high protein binding except
- a. Diazepam
  - b. Morphine
  - c. Tolbutamide
114. A patient presented with pain abdomen ataxia constipation. Peripheral blood smear examination showed basophilic stippling of RBC's. He is suffering from poisoning due to
- a. Iron
  - b. Lead
  - c. Cadmium
  - d. Arsenic
115. A patient was brought with history of pyrexia contracted pupils, Hypotension cyanosis progressing to coma is suspected to be suffering from poisoning due to
- a. Cannabis
  - b. Dhatura
  - c. Phenobarbitone
  - d. Diphenhydramine
116. A bullet which fails to leave the gun on firing but is ejected out with the subsequent shot is
- a. Dum dum bullet
  - b. Tandem bullet
  - c. Rocketed bullet
  - d. Rickochet bullet
117. Sexual asphyxia is associated with which of the following perversions
- a. Voyeurism
  - b. Masochism



- c. Sadism
  - d. Fetishism
118. Hysteroscopy is useful in all of the following except
- a. Uterine didelphis
  - b. Infertility
  - c. Still births
  - d. Vaginal bleeding
119. All of the following are used in post coital contraception except
- a. Danazol
  - b. Levonorgestrol
  - c. Ethinyl estradiol
  - d. Misoprostol
120. In the management of post partum haemorrhage all of the following can be used except
- a. Ergometrine
  - b. Carboprost
  - c. Misoprostol
  - d. Mefiprestone
121. A child was found to have pauci immune crescentic glomerulonephritis. The treatment to be given in this child is
- a. Methylprednisolone
  - b. Prednisolone + cyclophosphamide
  - c. Immunoglobulins
  - d. Cyclophosphamide
122. Post menopausal estrogen therapy causes increase in which of the following
- a. Cholesterol
  - b. VLDL
  - c. LDL
  - d. Triglycerides
123. FSH acts on which of the following cells primarily
- a. Stromal cells
  - b. Theca cells
  - c. Granulosa cells
  - d. Fibrin cells
124. A child presents with hypotonia and hyporeflexia. During its intrauterine period it had been seen that there was polyhydramnios and there was decreased foetal movements. The probable diagnosis is
- a. Congenital myasthenia
  - b. Spinal muscular atrophy
  - c. Muscular dystrophy
  - d. Congenital Myotonia

125. Most common cause of pseudohermaphroditism in a female is
- Ovarian dysgenesis
  - Congenital adrenal hyperplasia
  - Turners syndrome
  - PCOD
126. A newborn developed encephalitis and fever but there was no rash. Likely etiological agent is
- Meningococci
  - Herpes type 2
  - Streptococcal infection
  - Herpes type 1 infection
127. Bad prognostic indicator in ALL is
- Age greater than 1 year
  - Leukocyte count <50,000
  - Hypoploidy
  - Female sex
128. The most common site of adamantinoma of the long bones is
- Fibula
  - Tibia
  - Ulna
  - Femur
129. Which of the following sites is chondroblastoma of the femur likely to occur
- Metaphysis
  - Epiphysis
  - Diaphysis
  - Medullary cavity
130. An 8-year boy presented with pain in the arm. X ray of the humerus demonstrated an expansile lesion in the metaphysis with break in the cortex. The likely diagnosis is
- Chondroblastoma
  - Unicameral bone cyst
  - Aneurysmal bone cyst
  - Osteoclastoma
131. A torsional injury in the leg would most commonly cause lesion of
- Meniscus
  - Collateral ligament
  - Enchondral fracture
  - Anterior cruciate ligament tear
132. Twisting force in the leg would result in injury to all of the following except
- Anterior cruciate ligament
  - Capsular tear
  - Fibular collateral ligament
  - Meniscal tear

133. In RNTPC the schedule for sputum examination for category I patients is
- 2,3 and 5 months
  - 2,4 and 6 months
  - 1,3 and 5 months
  - 2,5 and 7 months
134. In a plague epidemic all of the following are done except
- Tetracycline prophylaxis to be given
  - Isolation of contacts
  - Susceptible to be vaccinated
  - Surveillance
135. In a study on comparison of a common drug(NSAID) and a rare drug (Dypirone) causing disease the attributable(AR) and relative risk (RR) were calculated. It will be found that the
- NSAIDS will have greater AR and RR as compared to Dypirone
  - NSAIDS will have lesser RR but greater AR
  - There will be no difference between the findings
  - NSAIDS will have lesser AR and RR
136. True morbidity in a population can be calculated by
- Sentinel surveillance
  - Active surveillance
  - Monitoring
  - Passive surveillance
137. Which of the following is best in evaluating the leprosy eradication programme
- Detection of new cases
  - The ratio of the multibacillary to the paucibacillary cases
  - The ratio of disability as compared to the new cases
  - Number of cases lepromin positive
138. In a negatively skewed curve
- The mean is less than the median
  - The mean is greater than the mode
  - The mean is equal to median
  - The mean and the mode are equal to 0
139. In a Chloroquine resistant zone the presumptive treatment of malaria to be given is
- Chloroquine +primaquine 45mg
  - Chloroquine + pyremethamine
  - Sulphalene 1000mgs
  - Sulphadoxine + pyremethamine
140. The drug having most rapid action on leprosy is
- Dapsone
  - Rifampicin
  - Clofazamine

d. Corticosteroids

a i p p g . c o m aiims papers

141. In a school of 100 students 1 of them developed measles on Jan 1st. Subsequently 35 children developed measles. Three on 3rd Jan. And the others 2 weeks later. The secondary attack rate of measles is
- 33.5%
  - 36.2
  - 35%
  - 37.5%
142. All of the following are associated with the use of DMPA except
- Cyclic bleeding
  - Change in quantity and quality of breast milk
  - Cyclic bleeding altered
  - Increased reproductive tract infection
143. Danazol is used in the treatment of
- Breast cysts
  - Cyclic mastalgia
  - Acyclyic mastalgia
  - Fibrous tumour
144. The period between primary and secondary case is known as
- Generation time
  - Serial interval
  - Incubation period
  - Multiplying time
145. Regarding poliomyelitis all of the following are true except
- Type I is associated with major epidemic
  - Type I is responsible for vaccine associated poliomyelitis
  - It is difficult to eradicate
  - Type I is given in higher quantity as compared to Type 2
146. A patient presented with stridor, which he developed after an attack of upper respiratory tract infection. On examination he was found to have a 3mm glottic chink. All of the following are used in the management except
- Tracheostomy
  - External arytenoidopexy
  - Teflon injection
  - Cordectomy
147. Normal anion gap metabolic acidosis is seen in which of the following conditions
- Renal failure
  - Diabetic ketoacidosis
  - Diarrhoea
  - Lactic acidosis

148. A 7-year child gave history fever for which she was treated with paracetamol following which the fever subsided. Later she developed seizures and altered sensorium. The urine examination revealed oxalate crystals on microscopy. Blood anion and osmolality gap were increased. The diagnosis is
- Paracetamol poisoning
  - Dithelene glycol
  - Renal tubular acidosis
149. Chondrocalcinosis is seen in which of the following conditions
- Hypervitaminosis D
  - Hypoparathyroidism
  - Oochronosis
  - Rickets
150. Endogenous polypeptide decreasing serum calcium levels is
- Calcitonin
  - Calcitriol
  - Parathormone
151. ST elevation is seen in all of the following conditions except
- Constrictive pericarditis
  - Ventricular aneurysm
  - Coronary artery spasm
  - MI
152. Which of the following physical signs is seen in a patient with severe aortic stenosis
- Holosystolic murmur
  - Diastolic rumble
  - Opening snap
  - Delayed upstroke of carotid
153. In a patient with myocardial infarction the valvular lesion commonly seen is
- Mitral regurgitation
  - Aortic regurgitation
  - Aortic stenosis
  - Septal defect
154. A patient had an antero inferior myocardial infarction and was in shock. The reason for the patient being in shock is
- Infarction causing septal defect
  - Right ventricular infarction
  - Decreased ejection fraction from left ventricle
  - Mitral regurgitation
155. In a patient vaccinated with Hepatitis B vaccine the serology would reveal presence of which of the following in his serum
- Anti IgM HBcAg
  - Anti HbsAG

- c. Anti IgG HBcAg
  - d. Anti HbeAg
156. In a patient with compensated liver cirrhosis presented with history of variceal bleed. The treatment of choice in this patient is
- a. Endoscopic sclerotherapy
  - b. Liver transplantation
  - c. TIPS (Trans jugular intrahepatic portal shunt)
  - d. Propranolol
157. A patient presented with headache and flushing. He has a family history of his relative having died of a thyroid tumour. The investigation that would be required for this patient would be
- a. Measurement of 5 HIAA
  - b. Measurement of catecholeamines
  - c. Intravenous pyelography
  - d. Chest x ray
158. A patient had undergone a renal transplantation 2 months back and now presented with difficulty breathing. X-ray showed bilateral diffuse Interstitial pneumonia. The probable etiologic agent would be
- a. CMV
  - b. Herpes virus
  - c. Ebstein Barr virus
  - d. Varicella
159. In a mycetoma foot infection, there are multiple discharging sinuses. The granules in the discharge are
- a. Pus cells
  - b. Fungal organisms
  - c. Inflammatory cells
  - d. Sulphur granules
160. Lateral aberrant thyroid implies
- a. Congenital thyroid abnormality
  - b. Metastatic foci from primary in thyroid
  - c. Lingual thyroid
161. Parathyroid most commonly involves which of the following sites
- a. Superior parathyroid lobe
  - b. Inferior parathyroid lobe
  - c. In the mediastinum
  - d. In the thyroid
162. Features to differentiate parathyroid adenoma from hyperplasia would include which of the following
- a. Presence of excess chief cells
  - b. Infiltration of capsule
  - c. Identifying hyperplasia involving all 4 glands at surgery in parathyroid hyperplasia
  - d. High levels of parathormone

163. Asbestosis of the lung is associated with all of the following except
- Progression of lesion even after stopping exposure to asbestos
  - Nodular lesions involving upper lobe
  - Asbestos bodies in sputum
  - Mesothelioma
164. Actinic keratosis predisposes to which of the following lesions commonly
- Basal cell carcinoma
  - Squamous cell carcinoma
  - Melanoma
  - Freckles
165. All of the following are true regarding Warthin's tumour except
- More common in females
  - 10% are bilateral
  - Commonly involve the parotid glands
  - They arise from the epithelial and the lymphoid cells
166. Which of the following mutations in a tumour suppressor agent causes breast carcinoma
- P43
  - P53
  - P73
  - P83
167. A female patient presented with a firm mass of 2\*2 cms in the upper outer quadrant of the breast. She gives a family history of ovarian carcinoma. The investigation that needs to be done to assess for mutation in
- BRCA2
  - Her2/Neu gene
  - P53
  - C-myc gene
168. For comparison grading of pain the scale used is
- Face's scale
  - Visual chart
  - CHEOPES
  - Numerical charts
169. Phelps sign is seen in
- Glomus jugulare
  - Vestibular schwannoma
  - Meniere's disease
170. Citelli's angle is
- CP angle
  - Dural sinus angle
  - Solid angle
  - Part of Mac Evans triangle

171. A child with cervical Ependymoma receives radiotherapy for his treatment. On follow-up he has been found to gain a lot of weight. The cause for his weight gain is
- Steroid induced obesity
  - Hypothalamic lesion
  - Hypothyroidism
  - Pan hypopituitarism
172. In a DNA the coding region reads 5-CGT-3. This would code in the RNA as
- 5-UAG-3
  - 5-ACG-3
  - 3-GCA-5
  - 3-ACG-3
173. A 10 year boy presented with polyuria , polydypsia Laboratory data showed (in meq) Na 154 , K 4.5 , serum osmolality 295 Bicarbonate 22 meq. Blood urea was 50 and specific gravity of urine 1.005. Diagnosis is
- Diabetes Insipidus
  - Renal tubular acidosis
  - Recurrent UTI's
  - Bartters syndrome
174. A lady presented with bilateral nodular lesions on shins. She was also found to have bilateral hilar lymphadenopathy on chest X-ray. Mantoux test reveals induration of 5 mms. Skin biopsy would reveal
- Non caeseating Granuloma
  - Vasculitis
  - Caeseating Granuloma
  - Malignant cells
175. In a patient with ascending paralysis there is subsequently respiratory muscle involvement. CSF examination showed albuminocytological dissociation. Treatment to be given is
- Oral Prednisolone
  - IV methyl Prednisolone
  - IV immunoglobulins
  - Cyclosporin
176. In a patient presenting with a swelling of the thyroid, the radionuclide scan showed a cold nodule and the ultrasound showed a non cystic solid mass. The management of this patient would be
- Lobectomy
  - Hemithyroidectomy
  - Eltroxin
  - Radio Iodine therapy
177. A patient presenting with jaundice the HIDA scan would be most useful for which of the following
- Biliary atresia
  - Bile duct carcinoma



- c. Cholelithiasis
  - d. Benign biliary disease
178. Insulinoma is most commonly located in which part of the pancreas
- a. Head
  - b. Body
  - c. Tail
  - d. Can be located at head neck or body equally distributed
179. In the synthesis of fatty acids the energy is supplied by
- a. NAD
  - b. NADPH
  - c. FAD
  - d. GTP
180. In a patient with frontal lobe abscess pigment released on exposure to UV rays showed red fluorescence. The organism implicated is
- a. Bacteroids
  - b. Peptostreptococci
  - c. Streptococci
  - d. Provetella
181. A patient operated for thyroid surgery for a thyroid swelling later in the evening developed difficulty in breathing. There was swelling in the neck. The immediate management would be
- a. IV calcium gluconate
  - b. Open the wound sutures in the ward
  - c. Epinephrine inj
  - d. Tracheostomy
182. Which of the following mechanisms is important in staphylococcal enterotoxin causing vomiting
- a. Increased activation of camp
  - b. Stimulation of vagal fibres
  - c. Release of IL-4 cytokine
  - d. Increased cGMP
183. The diagnosis of rota virus is made by
- a. Demonstration of Antibody in stool
  - b. Demonstration of antigen in stool
  - c. Direct visualization
  - d. Stool culture
184. Toxoplasmosis infection in the foetus can be best diagnosed by
- a. IgM antibody against toxoplasma in foetus
  - b. IgG antibodies against toxoplasma in foetus
  - c. IgM antibodies in mother

- d. IgG antibodies in mother
185. True about V Cholera is
- Pathogenicity of 0139 V.Cholera is due to the presence of the O antigen in it
  - One attack of V cholera gives life long immunity
  - Affects adults and children with equal propensity in non endemic regions
  - V.Cholera survives in the carriers in the inter epidemic period
186. Which of the following is associated with hypersensitive pneumonitis
- Asbestosis
  - Bysinosis
  - Berylliosis
  - Silicosis
187. Dr. Trehan, was accidentally exposed by a needle stick injury while taking sample of a patient who was HIV positive .The prophylaxis to be given is
- Zidovudine+Lamuvudine for 4 weeks
  - Zidovudine+Stamuvudine for 4 weeks
  - Ziduvudine+Lamuvudine+Nevirapine for 4 weeks
  - Ziduvudine +Lamuvudine +Indinavir for 4 weeks
188. Egg shell calcification is characteristically seen in
- Silicosis
  - Sarcoidosis
  - Asbestosis
  - Berylliosis
189. A patient presenting with polyuria, pain abdomen, nausea , altered sensorium was found to have bronchogenic carcinoma .The electrolyte abnormality seen in him would be
- Hypocalcemia
  - Hypercalcemia
  - Hypokalemia
  - Hyperkalemia
190. A patient presented with a swelling in his right foot with multiple discharging sinuses. The lesion did not respond to antibiotics. The likely etiological agent would be
- Actino-madura
  - Nocardia
  - Sporothrix
  - Madurella mycetoma
191. In Video assisted thoracoscopic surgery for better vision the space in the operative field is created by
- Co2 insufflation
  - Collapse of ipsilateral lung

- c. Self retaining retractor
  - d. Rib spacing
192. Which of the following malignancies would spread to cervical lymph nodes more commonly
- a. Nasopharyngeal carcinoma
  - b. Ca Base of tongue
  - c. Glottic Ca
  - d. Transglottic carcinoma
193. A patient presented with a 1 by 1.5 cms growth on the lateral border of the tongue. The treatment indicated in management of this patient is
- a. Laser ablation
  - b. External beam radiotherapy
  - c. Interstitial Brach therapy
  - d. Chemotherapy and Radiotherapy
194. A patient presented with a 3.5 cms size lymph node enlargement, which was hard and present in the submandibular region. Examination of the head and neck did not yield any lesion. The next investigation to be done in this patient is
- a. Triple endoscopy
  - b. Supra vital oral mucosal staining
  - c. Chest X ray
  - d. Laryngoscopy
195. A patient with solitary pulmonary nodule. The best investigation to come to a diagnosis would be
- a. MRI
  - b. CT scan
  - c. Ultrasound
  - d. Imaging guided FNAC