


# Kerala PSC Assistant Dental Surgeon Previous question paper

 [www.keralapscquestions.com/2016/01/kerala-psc-assistant-dental-surgeon.html](http://www.keralapscquestions.com/2016/01/kerala-psc-assistant-dental-surgeon.html)

## KPSC Assistant Dental Surgeon Health Services previous solved paper

(26) The accelerator solution for Zinc oxide eugenol impression paste contains,

- A) Silica
- B) Borax
- C) Potassium sulphate
- D) Calcium chloride

Answer: D

(27) The fluid resin technique is for;

- A) Fabrication of denture bases
- B) Pouring of casts
- C) Manipulation of alginate
- D) Manipulation of addition silicone

Answer: A

(28) The most popular implant material is

- A) Stainless Steel
- B) Nickel Chromium alloy
- C) Cobalt Chromium alloy
- D) Titanium

Answer: D

(29) The retarder present in alginate is

- A) Sodium phosphate
- B) Calcium sulphate
- C) Potassium titanium fluoride
- D) Zinc oxide

Answer: A

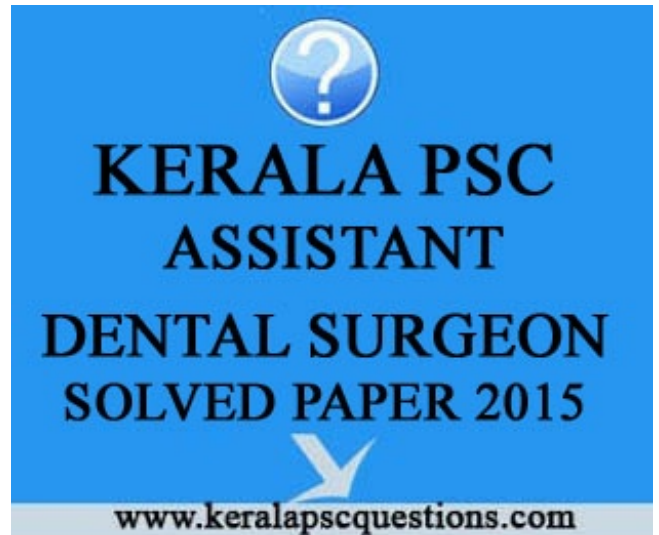(30) The component in inlay wax which improve its smoothness in molding and make it more resistant to cracking and flaking is

- A) Paraffin wax
- B) Gum dammar
- C) Carnauba wax
- D) Candelilla wax

Answer: B

(31) Lipschutz bodies are a common pathological feature of

- A) Sarcoidosis
- B) Primary Herpetic Stomatitis
- C) Syphilis



D) Recurrent Aphthous Stomatitis

Answer: B

(32) A sharp bend in the crown or root of a tooth results in

- A) Dilaceration
- B) Geminatio
- C) Turner's hypoplasia
- D) Concrescence

Answer: A

(33) Antoni Type A tissue and Antoni Type B tissue are characteristic features of

- A) Osteosarcoma
- B) Neurofibroma
- C) Schwannoma
- D) Neurofibrosarcoma

Answer: C

(34) . Characteristic lesions of Erythema multiforme are called

- A) Tzanck cells
- B) Nikolsky's sign
- C) Wickham's striae
- D) Bull's eye

Answer: D

(35) . Liesegang's rings and driven snow appearance are characteristic features of

- A) Calcifying epithelial odontogenic tumor
- B) Squamous odontogenic tumor
- C) Odontome
- D) Ameloblastoma

Answer: A

(36) . Most common malignancy of the oral cavity is

- A) Adenocarcinoma
- B) Basal cell carcinoma
- C) Malignant melanoma
- D) Squamous cell carcinoma

Answer: D

(37) Eburnation of Dentin is seen in

- A) Radiation caries
- B) Rampant caries
- C) Arrested caries
- D) Pit and fissure caries

Answer: C

(38) . Mucocele commonly occurs on the

- A) Upper lip
- B) Lower lip
- C) Buccal mucosa
- D) Palate

Answer: B

(39) Most common malignant salivary gland tumor in children

- A) Acinic cell carcinoma
- B) Polymorphous low grade adenocarcinoma
- C) Adenoid cystic carcinoma
- D) Mucoepidermoid carcinoma

Answer: D

(40) The virus group that is associated with Squamous Papilloma is

- A) Human Papovavirus
- B) Human Immunodeficiency virus
- C) Herpes simplex virus
- D) Paramyxovirus

Answer: A

(41) Disclosing agent is used to detect

- A) Dental caries
- B) Plaque
- C) Malocclusion
- D) Tooth vitality

Answer: B

(42) Most commonly used mouth wash

- A) Hydrogen peroxide
- B) Saline
- C) Chlorhexidine
- D) Sodium fluoride

Answer: C

(43) Safely tolerated dose of Fluoride is

- A) 8-16mg/kg body wt
- B) 16-32 mg/kg body wt
- C) 32-64mg/kg body wt
- D) 1-8mg/kg body wt

Answer: A

(44) 'Trench mouth' is the alternative name for

- A) Plaque induced gingivitis
- B) Herpetic gingivitis
- C) Acute necrotizing ulcerative gingivitis
- D) Eruption gingivitis

Answer: C

(45) First deciduous tooth to erupt into oral cavity

- A) Mandibular first molar
- B) Maxillary canine
- C) Maxillary central incisor
- D) Mandibular central incisor

Answer: D

(46) All are permanent restorative materials EXCEPT

- A) Glass ionomer
- B) Composite
- C) Amalgam
- D) Zinc oxide eugenol

Answer: D

(47) Brushing technique used in children

- A) Fones method
- B) Stillmanns metod
- C) Charters method
- D) Wilsons method

Answer: A

(48) Advantages of Glass ionomer cement are all EXCEPT

- A) Fluoride release
- B) Aesthetics
- C) Chemical bond
- D) Mechanical bond

Answer: D

(49) Normal Eruption sequence of deciduous teeth

- A) ABCDE
- B) ABDEC
- C) ABDCE
- D) EABCD

Answer: C

(50) Brudevold technique is used with

- A) Stannous fluoride
- B) APF
- C) Sodium Fluoride
- D) Fluoride varnish

Answer: B